Malacologia.

[Ann Arbor,Institute of Malacology]1962-
http://www.biodiversitylibrary.org/bibliography/12920

v.2 (1964-1965): http://www.biodiversitylibrary.org/item/47249
Page(s): Page 281, Page 282, Page 283, Page 284, Page 285, Page 286, Page 287, Page 288, Page 289, Page 290, Page 291, Page 292, Page 293, Page 294, Page 295, Page 296, Page 297, Page 298, Page 299, Page 300, Page 301, Page 302, Page 303, Page 304, Page 305, Page 306, Page 307, Page 308, Page 309, Page 310, Page 311, Page 312, Page 313, Page 314, Page 315, Page 316, Page 317, Page 318, Page 319, Page 320, Page 321, Page 322, Page 323, Page 324, Page 325, Page 326, Page 327, Page 328, Page 329, Page 330, Page 331, Page 332, Page 333, Page 334, Page 335, Page 336, Page 337, Page 338, Page 339, Page 340, Page 341, Page 342, Page 343, Page 344, Page 345, Page 346, Page 347

MALACOLOGIA, 1965, 2(3): 281-347

STUDIES ON THE STRUCTURE AND FUNCTION OF THE FEEDING APPARATUS OF *PHILINE APERTA* WITH A COMPARATIVE CONSIDERATION OF SOME OTHER OPISTHOBRANCHS

Anne Hurst

Department of Zoology
University of Reading
Reading, Berkshire, U.K.

ABSTRACT

A study has been made of the fine anatomy of the buccal region of ***Philine aperta*** (Linn.) and of the vascular and nervous supply of the anterior region of the body. An explanation of the functioning of the apparatus is given, based on observations of feeding, the varying relation of constituent parts of the buccal apparatus and the results of experimental stimulation and injection.

The walls of the buccal region are well provided with intrinsic muscles and are capable of great change in shape. They enclose a compact buccal mass in which the radula is supported by large muscles and a malleable tissue of vacuolated cells with cell inclusions and interspersed muscle fibres. This supporting tissue also serves as a base for muscle attachment, whilst one large pair of muscles also acts in closing the radula. The last is opened by 2 sets of oblique muscle fibres running in the buccal mass walls. Four pairs of small buccal tensors bind the buccal mass together. The intrinsic musculature maintains the shape and relationship of component parts of the buccal mass, causes its rising and sinking movements when releasing food to the oesophagus and is involved in movements of the teeth.

The buccal region is attached to the body wall by 6 pairs of extrinsic muscles which determine its topographical position. In feeding, 4 pairs of these pull the buccal region forward and the buccal mass is protruded so that the radula is well in advance of the mouth and can be used as a grab. Protrusion may be accompanied by extrusion and expansion of the anterior oesophagus to form a blood-filled extrovert, depending on specialization of the blood system and the degree of relaxation of separate bundles of the columellar muscle. These muscles open and close the mouth and control blood-flow to the anterior regions by their ability to constrict the anterior aorta. This vessel may also be constricted posteriorly where it passes through the diaphragm. It is confluent with many small haemal sacs and some large anterior sinuses involved in control of the protrusion and retraction of the proboscis. Withdrawal depends largely on strong contraction of the 6 pairs of proboscis retractors, which can also cause side-to-side and rotatory movements of the proboscis. The radula is short and each row of teeth comprises only a single pair of laterals. These pairs may be widely opened or closed so that adjacent ones interdigitate or can grasp food firmly. Opening depends on lateral pull of muscles with increased blood pressure below the radular membrane to flatten it, whilst in closing it is folded longitudinally by muscular pull from below.

Whilst many gastropods can protrude the buccal mass to a certain extent it has been shown that in ***Philine*** it can protrude further, forming part of a large gut extrovert. Use of the teeth does not depend on a bending plane nor is to and fro movement of the radular membrane involved. Some other opisthobranchs have been compared with *Philine* and their diet is given. Of these, *Scaphander lignar-*

ius (Linn.) is very similar, although the blood system does not exhibit so many adaptive changes. *Acteon tornatilis* (Linn.), *Cylichna cylindracea* (Pennant) and *Retusa* spp. do not use a proboscis; the probable method of feeding in *Acteon* and *Cylichna* is suggested. *Retusa* spp. have lost the buccal mass and feed by suction. Evolutionary trends are not readily traceable due to extreme adaptation of the buccal region for the mode of feeding.

INTRODUCTION

Feeding in gastropod molluscs normally depends on a radula and a buccal mass as the means of manipulating it. In most prosobranchs, the ability of the radular teeth to obtain food depends on the presence of a bending plane, first described by Ankel (1937). When the buccal mass is brought forward and sometimes slightly protruded the radular membrane is pulled out over it and flattened, so that the teeth are erected or spread out, thus achieving a suitable position for feeding. The buccal mass is so constructed as to produce a bending plane and cause the teeth to move over it. To this end the musculature is adapted and cartilaginous supports are a necessary adjunct.

Apart from Lemche's work on *Cylichna* (1956) no full account of the feeding apparatus in an opisthobranch has yet been given, and the method of obtaining food differs markedly from that outlined above. In *Philine aperta* (Linn.) the whole buccal mass may be protruded along with the anterior oesophagus so that the radula can grasp prey. There is considerable manoeuvrability of the protruded part and the use of the radular teeth does not depend on the existence of a bending plane. The teeth are erected by flattening of the radular membrane, which is achieved by lateral or oblique pulling of muscles inserted on its under surface. Further movement of the teeth depends on changing tensions in these muscles and closure is effected by downward pull on the radular membrane causing it to become deeply grooved in the median longitudinal plane. No cartilaginous support is present in the buccal mass but in other respects *Philine* is structurally similar to prosobranchs.

SECTION I

THE FEEDING APPARATUS OF *PHILINE APERTA*

1. GENERAL DESCRIPTION

Philine aperta is a tectibranch mollusc which lives in sublittoral sand, burrowing into the surface layers. It is a carnivore and has been described as feeding on small molluscs (Guiart, 1901; Förster, 1933; Fretter, 1939; Pruvot-Fol, 1954), young bivalves (Vayssière, 1880), Foraminifera (Brown, 1934; Fretter, 1939), naviculate diatoms, unicellular algae, planktonic remains (Fretter, 1939) and worms (Pruvot-Fol, 1954), whilst Vayssière (1880) also found remains of urchins and zooantharian spicules in the gut.

Small specimens collected off Plymouth and Helsingør had taken Foraminifera such as *Polystomella*, small rissoids and *Turbonilla elegantissima*, together with sand grains and miscellaneous small bottom debris. Brown (1934) suggested that *Philine* is a selective feeder since he found that the proportion of Foraminifera to sand grains was higher in the gut than in the bottom deposits. Some evidence in support of this has been found at Red Wharf Bay in Anglesey where larger specimens of *Philine* had been feeding almost exclusively on *Pectinaria*. A few had pieces of bivalve shells in their gizzards but there has been little other evidence of *Philine* feeding on bivalves.

Philine is able to take its prey in whole by means of a proboscis. This organ is not described by any of the above authors. Cuvier (1802, 1815) and Fretter (1939) mentioned that the odontophore is protracted with teeth opened to grab food, whilst Brown (1934) suggested that *Philine*

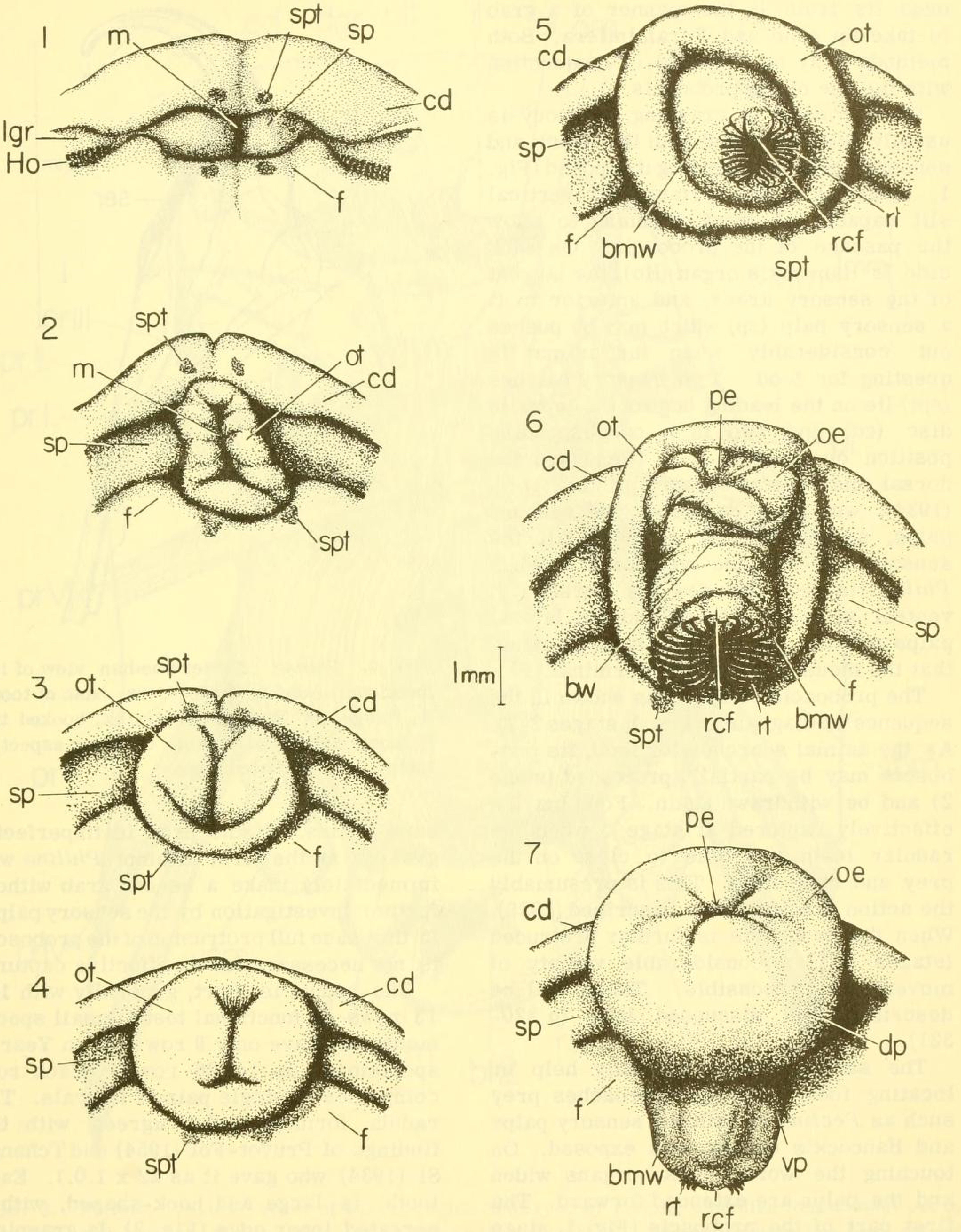

FIG. 1. *Philine:* anterior view showing stages (1-7) of protrusion of the proboscis. bmw, buccal mass wall; bw, buccal wall; cd, cephalic disc; dp, dorsal part of proboscis; f, foot; Ho, Hancock's organ; lgr, lateral groove; m, mouth; oe, oesophagus; ot, oral tube; pe, proboscis entrance; rcf, radular caecal fold; rt, functional radular tooth; sp, sensory palp; spt, sensory patch; vp, ventral part of proboscis.

uses its teeth in the manner of a grab to take up sand and Foraminifera. Both methods may be involved in conjunction with the use of the proboscis.

When *Philine* is crawling, its body is usually fully extended with the mouth and sensory areas surrounding it exposed (Fig. 1, stage 1). The former is a vertical slit capable of great widening to allow the passage of the proboscis. On each side is Hancock's organ (Ho), the largest of the sensory areas, and anterior to it a sensory palp (sp) which may be pushed out considerably when the animal is questing for food. Two sensory patches (spt) lie on the leading edge of the cephalic disc (cd) and two in a corresponding position on the foot (f). These are the dorsal and ventral sensory pits of Brown (1934), who also described the sensory palps, as did Fretter (1939). All the sensory areas are yellowish. When *Philine* is not extended the dorsal and ventral sensory patches and the lateral palps may be drawn in to such an extent that the mouth becomes subterminal.

The proboscis emerges as shown in the sequence of diagrams (Fig. 1, stages 2-7). As the animal searches for food, its proboscis may be partially protruded (stage 2) and be withdrawn again. Food may be effectively captured at stage 5 when the radular teeth are able to close on the prey and drag it in. This is presumably the action which Fretter described (1939). When the proboscis is further protruded (stages 6-7) a considerable variety of movements is possible. These will be described and discussed later (p 320-321).

The sensory areas probably help in locating food. *Philine* approaches prey such as *Pectinaria* with the sensory palps and Hancock's organs well exposed. On touching the worm, these organs widen and the palps are extended forward. The first part of the proboscis (Fig. 1, stage 2) is shot out, swiftly reaching stage 5, with the radular teeth opening as they appear. The widely spread teeth then close on the worm, pulling it in whole, often with at least part of its tube of sand grains. If the prey is imperfectly grasped at the first attempt *Philine* will immediately make a second grab without further investigation by the sensory palps. In this case full protrusion of the proboscis is not necessary for an effective capture.

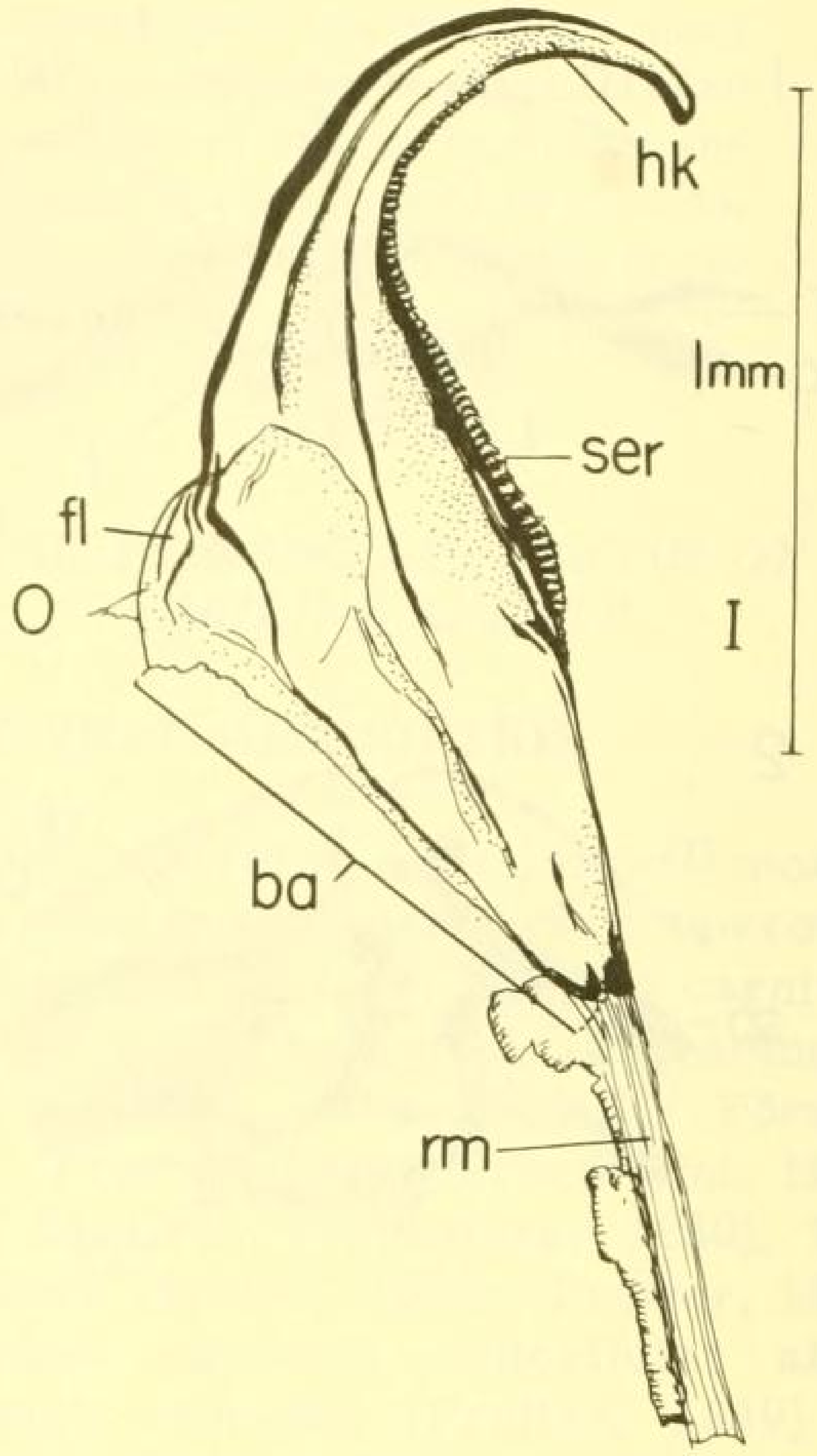

FIG. 2. *Philine*. Posteromedian view of left functional radular tooth. ba, base of tooth; fl, flange (of Brown, 1934); hk, hooked tip; I, inner aspect of tooth; O, outer aspect of tooth; ser, serrated edge.

The radula is short, generally with 12-13 rows of functional teeth (small specimens may have only 9 rows) or in Year II specimens, up to 26 rows. Each row comprises a single pair of laterals. The radula formula 1.0.1 agrees with the findings of Pruvot-Fol (1954) and Tchang-Si (1934) who gave it as 22 x 1.0.1. Each tooth is large and hook-shaped, with a serrated inner edge (Fig. 2). In grasping, the pairs of teeth interdigitate and allow a firm grip to be maintained on the prey.

Specimens of *Philine* collected varied in total length from 1.5-4.5 cm. An animal useful for experiments was 3 cm

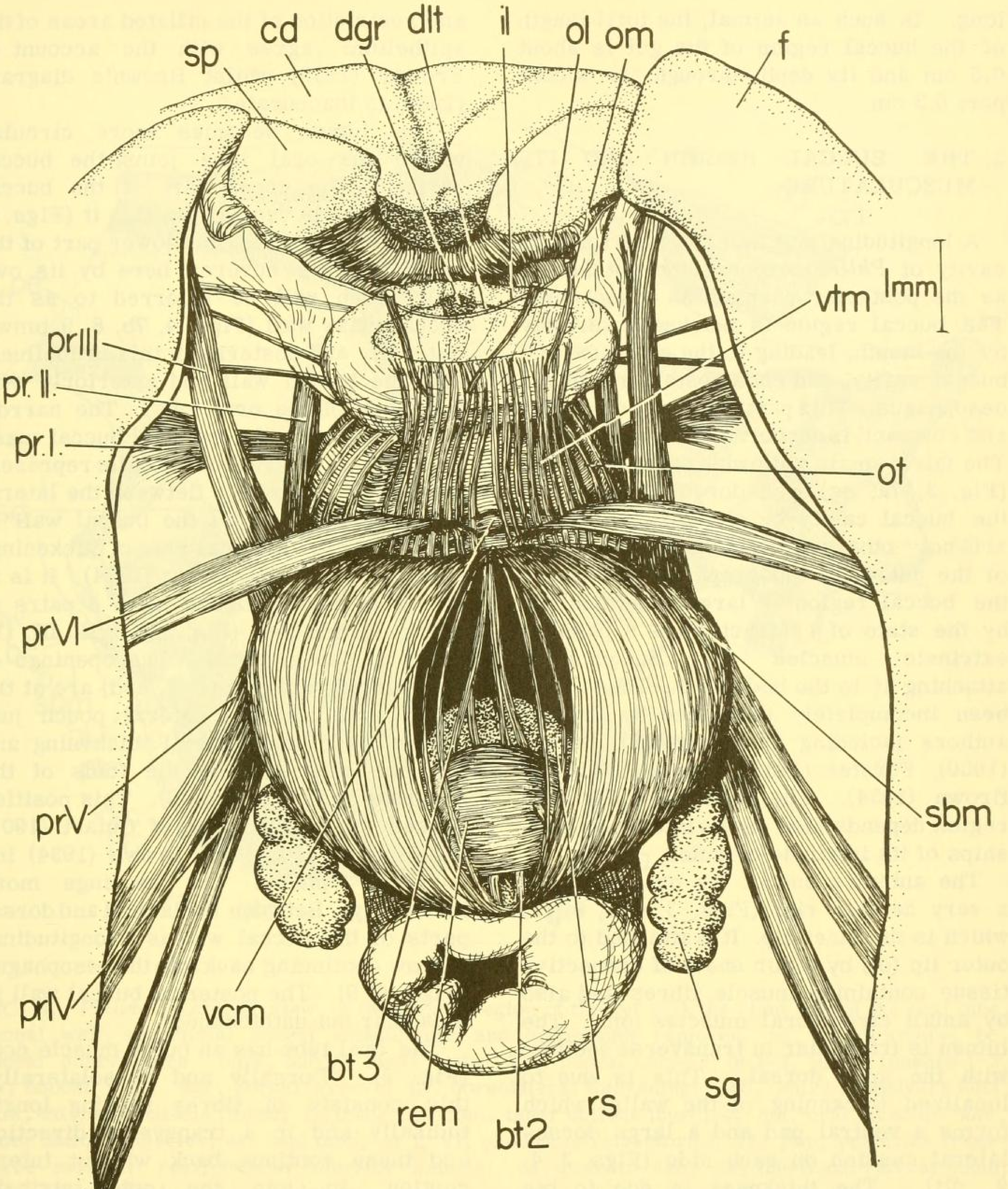

FIG. 3. *Philine.* Ventral view of buccal region displayed by making a median longitudinal cut in the foot and pinning it out. Muscles pr VI are thus stretched. The oesophagus has been cut off near its anterior end. The connective tissue sheet between the inner and outer lips has been freed ventrally and the ventral oral muscles have been cut from their origins. bt 2, 3, buccal tensors 2, 3; cd, cephalic disc; dgr, dorsal groove; dlt, dorsolateral thickening; f, foot; il, inner lip; ol, outer lip; om, oral muscle; ot, oral tube; prI–VI, proboscis retractors I–VI; rem, radular elevator muscle; rs, radular sac; sbm, superficial buccal musculature; sg, salivary gland; sp, sensory palp; vcm, ventral circular muscle; vtm, ventral tensor muscle.

long. In such an animal, the total length of the buccal region of the gut is about 0.5 cm and its depth through the widest part 0.3 cm.

2. THE BUCCAL REGION AND ITS MUSCULATURE

A longitudinal cut into the anterior body cavity of *Philine* exposes the gut as far as the posterior part of the oesophagus. The buccal region is marked anteriorly by the mouth, leading to the oral tube and buccal cavity, and ends posteriorly at the oesophagus. This part of the gut, muscular and compact, is concerned with food intake. The fairly small, yellowish salivary glands (Fig. 3, 7a, sg) open dorsolaterally into the buccal cavity by short ducts. They are not otherwise attached to the walls of the gut. The topographical position of the buccal region is largely determined by the state of contraction of 6 pairs of extrinsic muscles (Fig. 3, pr I-VI) attaching it to the body wall. These have been incompletely described by several authors including Cuvier (1802), Guiart (1900), Förster (1933), Tchang-Si (1934), Brown (1934). The shape of the buccal region depends also on the inter-relationships of its intrinsic muscles.

The anterior end of the oral tube has a very definite rim (Figs. 3, 4, 5, 9, 11) which is the inner lip. It is attached to the outer lip (ol) by a thin sheet of connective tissue containing muscle fibres and also by small circumoral muscles (om). The lumen is triangular in transverse section, with the apex dorsal. This is due to localized thickening of the walls, which forms a ventral pad and a large dorsolateral cushion on each side (Figs. 3, 4, 9, dlt). The thickness is due to big connective tissue cells with interspersed radial muscle fibres. In the contracted and shortened oral tube, these cushions may meet and close the lumen. The epithelium of the oral tube is columnar and is ciliated along the apex of the lumen, which thus constitutes a dorsal groove (Figs. 3, 4, 9, dgr) continuing back into the oesophagus. The shape of the lumen and restriction of the ciliated areas of the epithelium agree with the account of Fretter (1939) whilst Brown's diagram (1934) is inaccurate.

The lumen becomes more circular where the oral tube joins the buccal cavity. The upper part of the buccal mass projects ventrally within it (Figs. 4, 7b, 9) almost filling the lower part of the cavity. It is covered here by its own wall which will be referred to as the buccal mass wall (Figs. 4, 7b, 8, 9, bmw). Laterally and posteriorly this is confluent with the buccal wall and anteriorly with the floor of the oral tube. The narrow spaces between the vertical buccal mass wall and the lateral buccal walls represent the lateral pouches. Between the lateral and posterior part of the buccal wall is a very marked vertical area of thickening, also mentioned by Brown (1934). It is in this region that fibres from 4 pairs of extrinsic muscles (Fig. 5, pr II, III, IV, V) enter the gut wall. The openings of the salivary ducts (Fig. 4, esd) are at the upper end of each lateral pouch just posterior to the vertical thickening and may be obscured by the folds of the oesophagus (as in Fig. 9). This position agrees with the figures of Guiart (1901) and Fretter (1939) but Brown (1934) incorrectly placed the openings more anteriorly. Between the lateral and dorsal parts of the buccal wall is a longitudinal furrow continuing back into the oesophagus (Figs. 4, 9). The posterior buccal wall is muscular but unthickened.

The oral tube has an outer muscle coat (Fig. 5). Dorsally and dorsolaterally, this consists of fibres running longitudinally and in a transverse direction and these continue back without interruption to join the outer intrinsic musculature of the oesophagus. Laterally and ventrally the transverse fibres of the oral tube become much more numerous and form a sphincter-like group, the ventral circular muscles (Figs. 3, 5, vcm). Overlying these are 2 tracts of longitudinal fibres, the ventral tensor muscles (Figs. 3, 5, vtm) each divided into several groups, extending from the

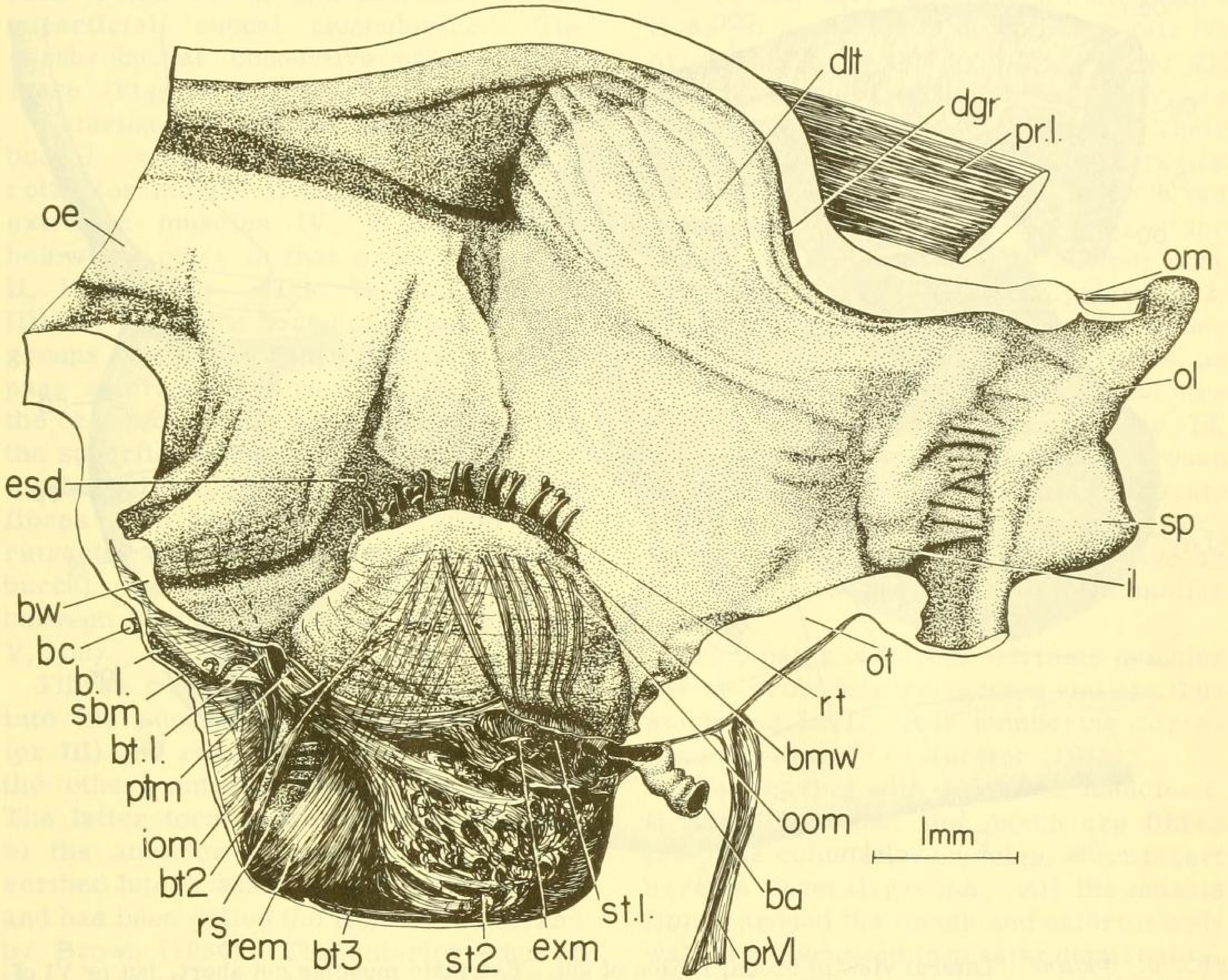

FIG. 4. *Philine*. Lateral view of the buccal region of the gut with the right half of the oral tube, buccal wall, superficial buccal musculature and oesophagus removed. ba, buccal artery; bc, buccal commissure; bmw, buccal mass wall; b 1, buccal nerve 1; bt 1-3, buccal tensors 1-3; bw, buccal wall; dgr, dorsal groove; dlt, dorsolateral thickening; esd, entry of salivary duct; exm, extrinsic muscle fibres; il, inner lip; iom, inner oblique muscles; om, oral muscle; oom, outer oblique muscles; ot, oral tube; pr I, VI, proboscis retractors I, VI; ptm, posterior transverse muscle; rem, radular elevator muscle; rs, radular sac; rt, functional radular tooth; sbm, superficial buccal musculature; sp, sensory palp; st 1, 2, supporting tissues 1, 2.

oral rim to the anterior limit of the buccal mass.

The buccal mass contains the radular apparatus and intrinsic muscles concerned with its functioning. Its lower part projects ventrally posterior to the oral tube. It is covered with a loose sling-like muscle coat, the superficial buccal musculature (Figs. 3, 4, 5, 8, 9, sbm), briefly described by Brown (1934). It extends from just posterior to the insertions of retractor muscles II, III, IV and V and beneath the ventral edge of the oesophagus to cover the posterior and

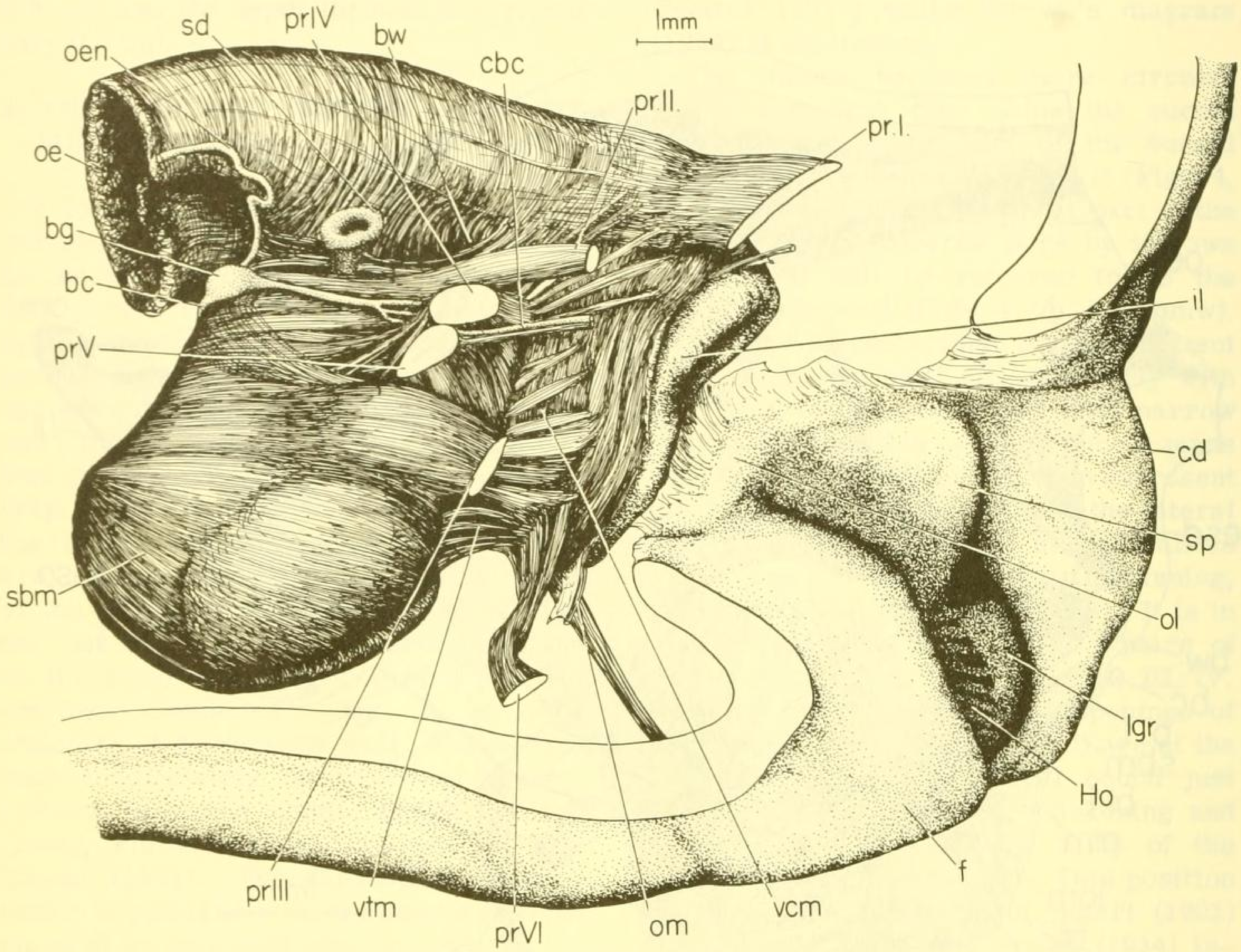

FIG. 5. *Philine.* Lateral view of buccal region of gut. Extrinsic muscles cut short, but pr VI of left side is in situ. Right side of body wall removed from centre foot to right of the median line of the cephalic disc. The latter has been pulled forward. bc, buccal commissure; bg, buccal ganglion; bw, buccal wall; cbc, cerebrobuccal connective; cd, cephalic disc; f, foot; Ho, Hancock's organ; il, inner lip; lgr, lateral groove; oe, oesophagus; oen, oesophageal nerve; ol, outer lip; om, oral muscles; pr I–VI, proboscis retractors I–VI; sbm, superficial buccal musculature; sd, salivary duct; sp, sensory palp; vcm, ventral circular muscles; vtm, ventral tensor muscles.

lateral parts of the buccal wall and surround the lower part of the buccal mass. It is attached to the last anteriorly. Ventrally, it is partially open and partially attached to the intrinsic muscles; the extent of attachment is variable. The superficial buccal musculature receives a large number of contributory fibres from the extrinsic retractor muscle pair II (Fig. 5). These enter the lateral buccal walls at the upper ends of the vertical thickenings a short distance anterior to the salivary glands. They are linked across the midline by a band of fibres running below the oesophagus, and marking the upper posterior limit of the superficial buccal musculature. A few fibres pass dorsal to the salivary ducts, most below them. This band, linking right and left retractor muscles II, is partly hidden by the buccal ganglia and their commissure (Figs. 5, 6, 7a, 9, bg, bc) which lie on the junction between buccal wall and oesophagus. A second group of fibres passes ventrally from each retractor II and fans out in the superficial buccal musculature. The cerebrobuccal connective passes under these (Figs. 5, 7a, cbc).

Entering the vertical thickening of the buccal wall immediately ventral to retractor muscle II on each side are the extrinsic muscles IV, V and III, one below the other in that order (Fig. 5, pr II, IV, V, III; Figs. 7a, 7b, pr IV, V, III). From the bases of IV and V some groups of fibres fan out obliquely. Some pass anteriorly to insert superficially on the oral tube, some posteriorly either into the superficial buccal musculature or on to the buccal wall (Fig. 5, pr IV, V). A few fibres also pass anteriorly from each retractor muscle V alongside the cerebrobuccal connective as it emerges from between retractor muscles IV and V (pr V, cbc).

Fibres pass back from each muscle III into the superficial buccal musculature (pr III) and some pass from one side to the other, anterior to the buccal mass. The latter form a narrow strip attached to the anterior transverse muscle (described later), which is rather conspicuous and has been called the transverse strand by Brown (1934). The anterior edge of the superficial buccal musculature attaches to this strand and so do the posterior ends of the ventral tensor muscles (Figs. 3, 5, sbm, vtm).

Fibres from the 4 pairs of extrinsic muscles also enter the buccal mass more deeply, passing through the vertical thickening of the buccal wall and many, mostly from retractor muscle III and to a less extent from muscles IV and V, enter the anterior transverse muscle (Fig. 8, exm, atm) of the buccal mass. This muscle runs across joining the bases of the vertical thickenings on each side (Figs. 4, 8, st 1). Its position has been described by Brown (1934) and will be discussed further (p 294).

Another 2 pairs of extrinsic muscles (Figs. 3, 4, 5, 9, pr I, pr VI) insert on the oral tube - pr I dorsolaterally, pr VI ventrally. The origins of pairs I, II and III lie near the mouth (Fig. 14, pr I, II, III) so that they run towards their insertions in a posterior direction. Pair VI originates from the foot (Fig. 14, pr VI) whilst retractor muscles IV and V are branches of the columellar muscle. Their origins lie posterior to the buccal region of the gut. Previous authors have not mentioned their columellar nature and have not agreed as to whether they represent 1 or 2 muscles (Cuvier, 1802; Förster, 1933). In fact, they are sometimes connected near their insertions, as suggested by Förster (1933), and are innervated by a common nerve (Fig. 14, p 9). The visceral loop passes between the 2 muscles where they are separate and not through either as Cuvier (1802) indicated. Förster (1933) also gave an incomplete account of the columellar muscle.

All 6 pairs of buccal extrinsic muscles act as proboscis retractors and are thus numbered I-VI. This numbering corresponds with I-VI of Förster (1933).

Interweaving with retractor muscles I, II and III around the mouth are fibres from the columellar muscles, which insert here in several groups. All the muscle fibres around the mouth and anterior body wall are discussed in greater detail below.

Within the anterior part of the body cavity the columellar muscle is restricted to discrete longitudinal bands (VII, VIII, IX, of Förster, 1933). These include a median columellar muscle (Fig. 6, mcm) and a lateral columellar muscle (lcm) on each side. The lateral muscles are variable and each may run as a single or double tract (shown double in Fig. 6) superficially embedded in the muscles of the body wall. At the anterior end they branch to produce an inner and an outer branch (Fig. 6, ilc, olc). The inner branch of the right lateral columellar has a double origin and the anterior aorta (aa) passes between the 2 parts. Proboscis retractors V leave the lateral tracts midway between diaphragm and insertion. Proboscis retractors IV leave columellar fibres running in the foot at a slightly posterior and more dorsal level.

The median columellar muscle is not embedded in the foot except superficially near the diaphragm. Here all the longitudinal tracts of the columellar muscle unite, with the addition of some muscle fibres from the body wall. The unified muscle then enters the visceral haemocoel and finally reaches its origin on the shell. Cuvier (1802, 1815) described the shell as completely unattached to muscles.

The mouth is a narrow vertical aperture. Its outer lip is formed by the leading edges of cephalic disc and foot and the sensory palps (Fig. 1, m, cd, f, sp). These areas may be pulled in, becoming folded longitudinally (as in Figs. 5, 14) and forming a closed funnel at the posterior end of which is the mouth. The anterior end of the foot is drawn into the funnel mid-ventrally by the median columellar muscle. The sensory palps and cephalic disc are pulled in by the lateral columellar muscle.

The median columellar muscle gives small branches to the reproductive system and to the foot (Fig. 16, fcm) a little posterior to the origins of the proboscis retractors. The remainder of its fibres insert on each side of the tip of the foot, and the longest ones reach the insertion of the lateral columellar muscle. The inner and outer anterior branches of each lateral columellar muscle run parallel to each other. The inner inserts adjacent to the sensory palp, the outer slightly more laterally (Figs. 6, 16, ilc, olc). Both branches give groups of fibres passing to insertions on the cephalic disc

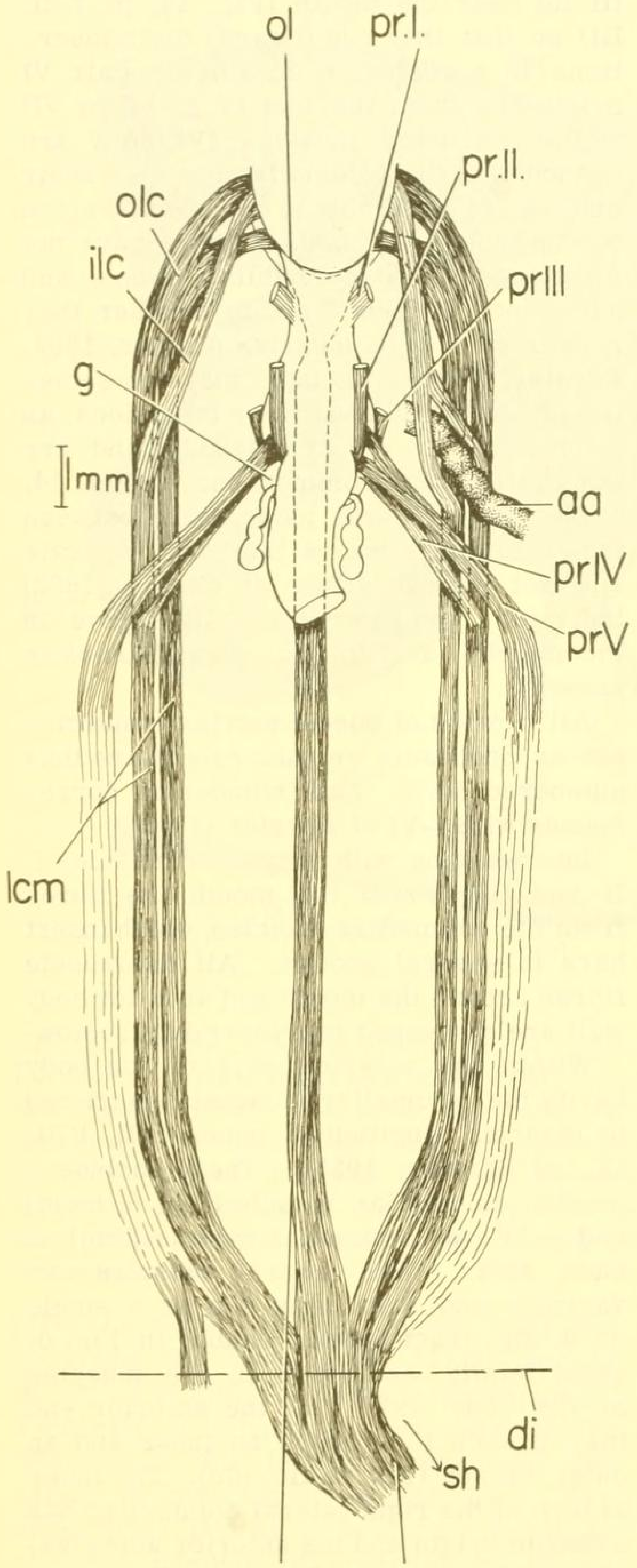

FIG. 6. *Philine.* Diagrammatic representation of columellar muscle with the buccal region of the gut in situ. aa, anterior aorta; cm, undivided columellar muscle; di, region of diaphragm; g, gut; ilc, inner branch of lateral columellar muscle; lcm, lateral columellar muscle; mcm, median columellar muscle; ol, outer lip; olc, outer branch of lateral columellar muscle; pr I-V, proboscis retractors I-V; sh, shell.

and foot (Figs. 14, 16).

Median and slightly dorsal to the insertion of the inner branch of each lateral columellar muscle is the origin of one of the pair of proboscis retractors II (Figs. 14, 16, pr II). This origin is quite narrow, with fibres emerging from the cephalic disc and joining to form a fairly small flat band going back towards the buccal mass. The origin of each pair III (Figs. 14, 16, pr III) is similar but wider since the muscle is a larger one, also flat and strap-like. These origins are situated in the foot lateral to the median columellar muscle and fibres from this go both over and under pair III to insert widely on the anterior tip of the foot.

A much wider origin altogether is that of each proboscis retractor I (Figs 3, 14, pr I). On each side it includes fibres arising from a position ventral and lateral to the origin of retractor muscle II but median to the insertion of the lateral columellar muscle. These fibres are joined by others from a wide origin on the anterior part of the cephalic disc. The 2 groups join on each side to form a flat muscle shortly inserting on the oral tube. The more dorsal side of the muscle, composed of fibres from the cephalic disc, inserts more posteriorly on the oral tube and these fibres are thus those of the greatest length within the muscle.

The proboscis retractors VI are another pair of muscles each with a wide origin on the anterior part of the body wall (Figs. 14, 16, pr VI). These leave the foot a short distance posterior to the mouth. Each origin is oblique, the more median end being more posterior. The fibres constituting each of pair VI quickly approach one another to form a strap-like muscle going towards its insertion on the oral tube, where the fibres again become slightly splayed (Figs. 3, 5, 9, 14, 16, pr VI).

Posterior to the origin of each retractor muscle VI a few strands travel together to insert in the foot. They are from the median columellar muscle (Fig. 14, fcm). These strands together with retractor muscles VI and I are closely associated with the walls of certain blood sinuses and with nerves to be described below (Fig. 14). Several fine muscle strands travel within the sinus walls in seemingly random directions.

Dissection allows the buccal mass to be investigated and the relations of its constituent parts clarified. The superficial buccal musculature is readily removed and immediately the underlying pigmented buccal wall is exposed (Fig. 7a, bw) together with some intrinsic muscles concerned with the buccal mass (Fig. 7, bt 1-3, ptm, rem), large areas of supporting tissue (Fig. 4, st 1, st 2, Fig. 7, st 2) and part of the radular sac (Figs. 4, 7, rs).

The buccal wall receives fibres running obliquely from muscles IV, V and III (Fig. 7a, bw). Attached to its ventral edge is a prominent muscle - the posterior transverse muscle (ptm). This muscle receives contributory fibres from III at each side (pr III). Its fibres fan out on either side to insert on the supporting tissues (Figs. 4, 7, 8, ptm, st 1, st 2). From its centre muscle fibres emerge and join in groups to form 2 pairs of small muscles (Figs. 7, 8, bt 1, bt 2). One pair (bt 1) travels dorsalwards to insert on the ventral wall of the oesophagus. (In Fig. 7a, the upper edge of the superficial buccal musculature is not removed, and bt 1 may be seen passing under it.) The second pair (bt 2) goes to the ventral tip of the radular sac (Figs. 4, 7, 8, bt 2, rs). Obscuring its insertion here is the large U-shaped radular elevator muscle (Figs. 3, 4, 7, 8, 9, rem) running transversely below the radular sac and turning on each side to disappear beside it under the buccal wall. This is the muscle P of Brown (1934). He also shows a muscle W which represents rom and st 2 in the present account.

If a cut is now made along the upper dorsal edge of the posterior transverse muscle, continued vertically immediately posterior to the bases of retractor muscles III, IV, V and II and across the ventral edge of the oesophagus, this will result in complete removal of the posterior buccal wall, leaving a window through

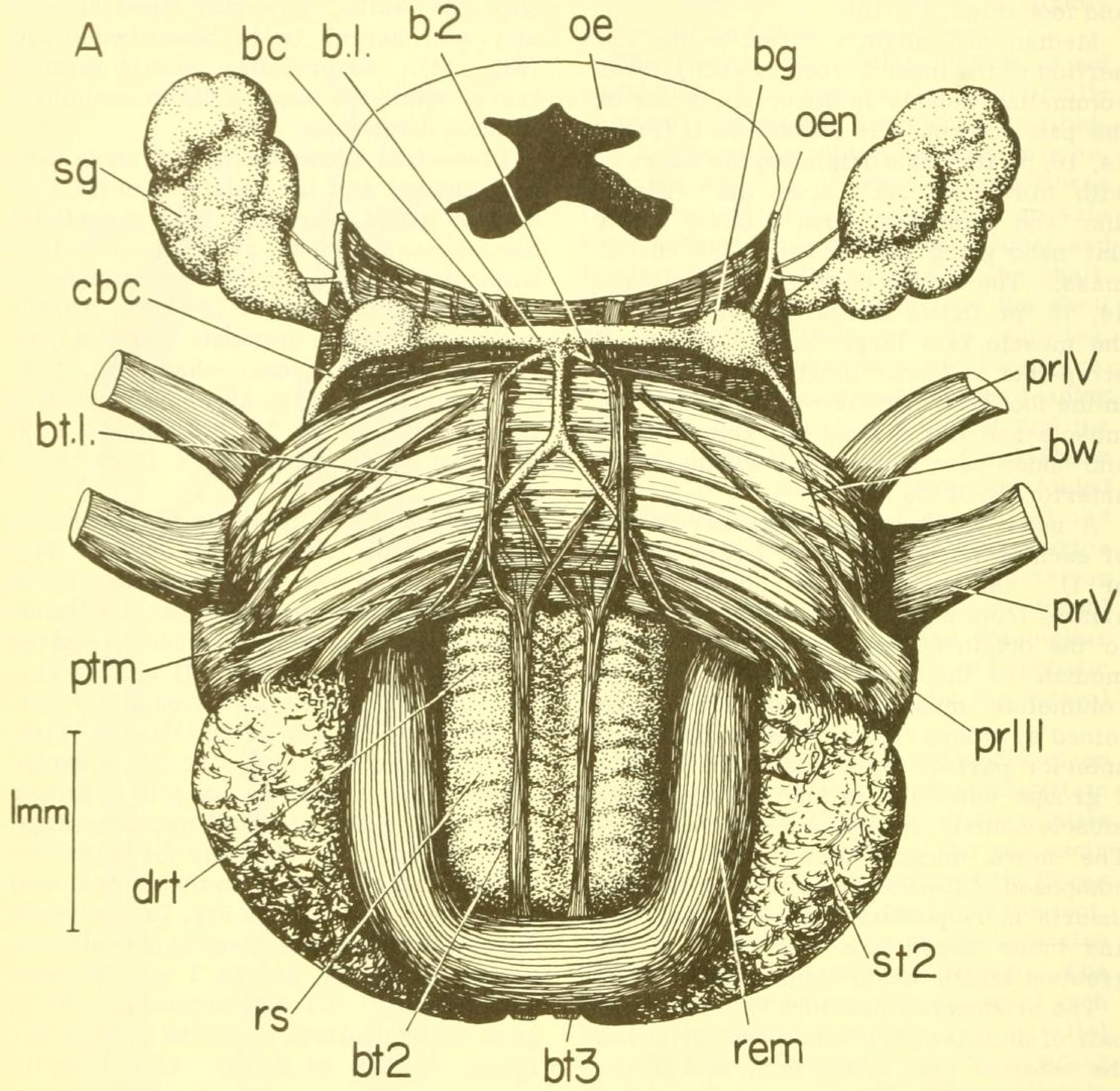

FIG. 7. *Philine.* Successive dissections of the buccal region of the gut in ventroposterior view. a: the superficial buccal musculature has been removed and the proboscis retractors IV and V cut short.

which the cylindrical upper half of the buccal mass can be seen, entirely surrounded by the buccal mass wall (Fig. 7b). This wall is bounded at the lower edge by the posterior transverse muscle (bmw, ptm). Dorsally it turns in around the radula and passes beneath the radular membrane (Figs. 4, 7b, 8, 9, rm).

When at rest, the short radular membrane has a median longitudinal fold forming a V-shape in transverse section and bringing the tooth-bearing surfaces together. Hence the teeth stand up almost vertically (Figs. 4, 7b, 8, 9, rt) with the hooked tips from each side interdigitating. The short row of crossed hooks can be seen by looking on to the top of the cylindrical mass. If the central posterior part of the buccal mass wall and posterior transverse muscle is also removed (Fig.

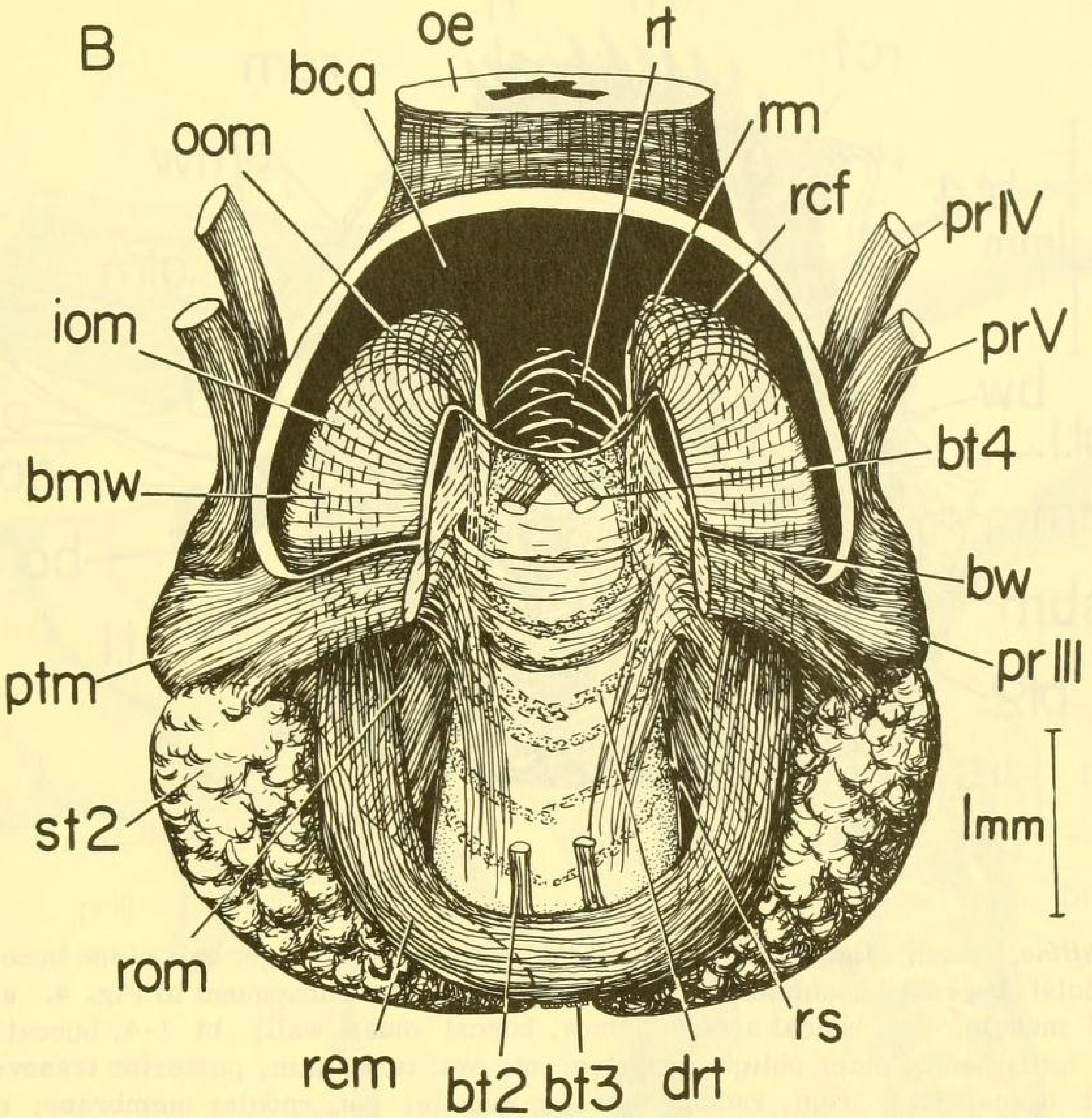

FIG. 7. *Philine.* Successive dissections of the buccal region of the gut in ventroposterior view. b: after removal of the buccal ganglia, their nerves, the salivary glands and the posterior part of the buccal wall, a window has been cut in the posterior buccal mass wall, and the central part of the posterior transverse muscle cut away. b 1, 2, buccal nerves 1, 2; bc, buccal commissure; bca, buccal cavity; bg, buccal ganglion; bmw, buccal mass wall; bt, 1-4, buccal tensors 1-4; bw, buccal wall; cbc, cerebrobuccal connective; drt, developing radular tooth; iom, inner oblique muscles; oe, oesophagus; oen, oesophageal nerve; oom, outer oblique muscles; pr III-V, proboscis retractors III-V; ptm, posterior transverse muscle; rcf, radular caecal fold; rem; radular elevator muscle; rm, radular membrane; rom, radular occlusor muscle; rs, radular sac; rt, functional radular tooth; sg, salivary gland; st2, supporting tissue 2.

7b) the upper end of the short vertical radular sac is exposed (rs). Its posterior wall bends forward partially closing the radular sac before bending outwards again to join the buccal mass wall. This transverse fold, the radular caecal fold (Figs. 7b, 8, 9, rcf) is referred to by Brown (1934) as the posterior lobe, and lies between the developing radular teeth (Figs. 7, 9, drt) and the functional ones (Figs. 4, 7b, 8, 9, rt). The insertions of the pair of buccal tensors (bt 4) are on the central part of the radular caecal fold (Figs. 7b, 8, 9, bt 4). Each travels obliquely outwards to the posterior transverse muscle (Figs. 8, 9, bt 4, ptm).

The buccal mass wall is thickened with connective tissue, especially laterally (Figs. 8, 9, bmw). Some muscle fibres enter it from the posterior transverse

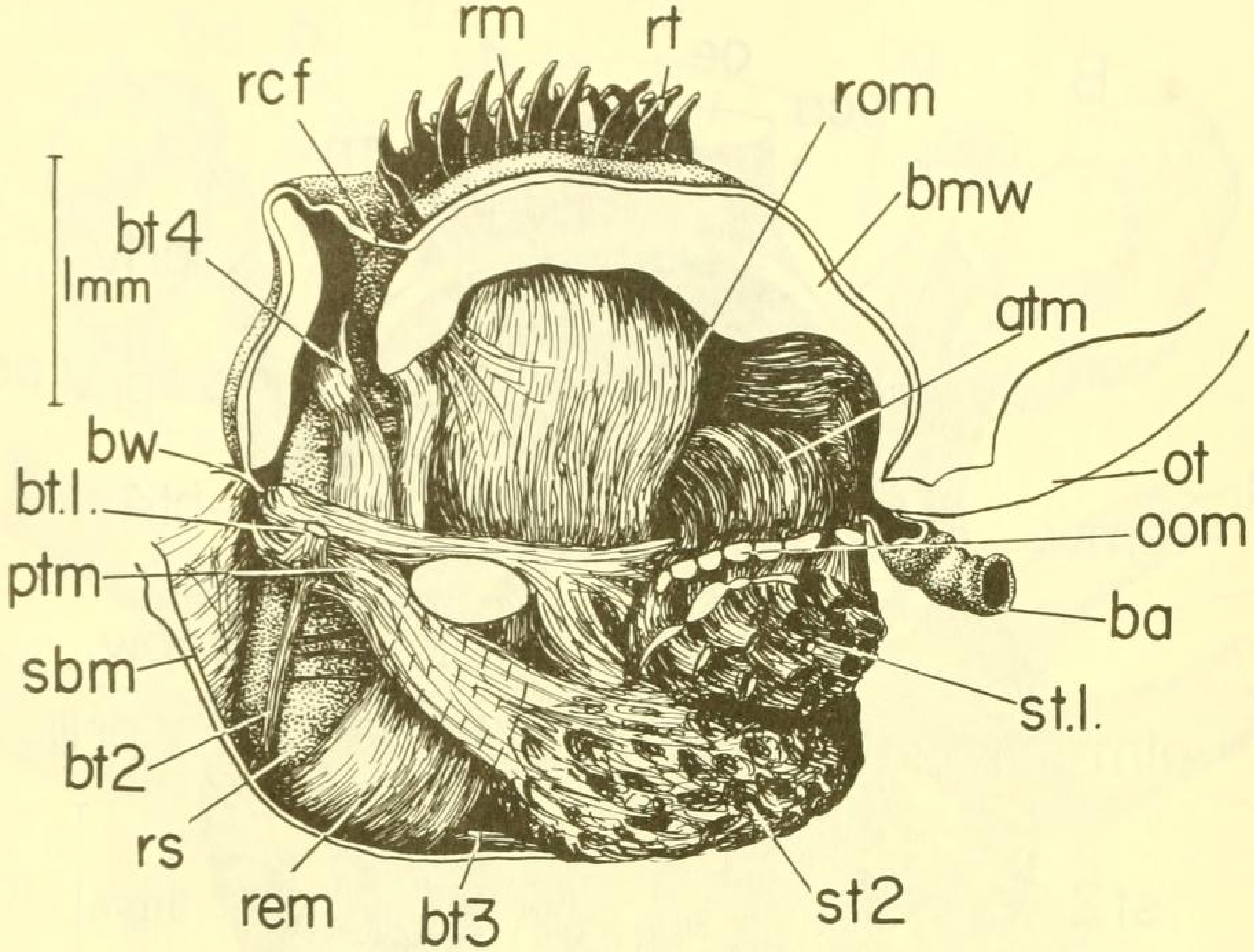

FIG. 8. *Philine.* Right lateral view of the buccal mass with the right half of the buccal mass wall and superficial buccal musculature removed, in dissection subsequent to Fig. 4. atm, anterior transverse muscle; ba, buccal artery; bmw, buccal mass wall; bt 1-4, buccal tensors 1-4; bw, buccal wall; oom, outer oblique muscles; ot, oral tube; ptm, posterior transverse muscle; rcf, radular caecal fold; rem, radular elevator muscle; rm, radular membrane; rom, radular occlusor muscle; rs, radular sac; rt, radular tooth; sbm, superficial buccal musculature; st 1, 2, supporting tissues 1, 2.

muscle, including the buccal tensors 2 (Fig. 4, bt 2). They interweave with circular fibres running in the wall. Also obvious are 2 sets of oblique muscle fibres each arranged in several almost parallel groups (Figs. 4, 7b). The inner set (iom) originates from the radular elevator muscle (rem) which enters the buccal mass wall on each side, lateral to the radular sac and between the fibres of the posterior transverse muscle (Fig. 8, rem, ptm). These inner oblique muscle fibres run through the wall and over its dorsal edge to insert on the under surface of the radular membrane. The outer oblique muscles (Figs. 4, 7b, oom) also insert here but travel at right angles to the inner set. They originate from the supporting tissue (st 1) lateral to the anterior transverse muscle (Fig. 8, st 1, atm, oom). The oblique muscles of the buccal mass wall were inadequately described by Brown (1934), who referred to the outer set as X1 and X2.

The anterior transverse muscle is extremely large (Figs. 8, 9, atm). It receives contributory fibres from retractors III, IV and V and is embedded in connective tissue at either end. The latter forms an important support (Figs. 4, 8, st 1) for the buccal mass and is a region for muscle attachment (p 289). In fresh animals, it often contains white granules described as calcium salts and glycogen by Gabe & Prenant (1952). It consists of elongated cells with large vacuoles and fibrous walls. Muscle fibres run between the cells. Closely attached

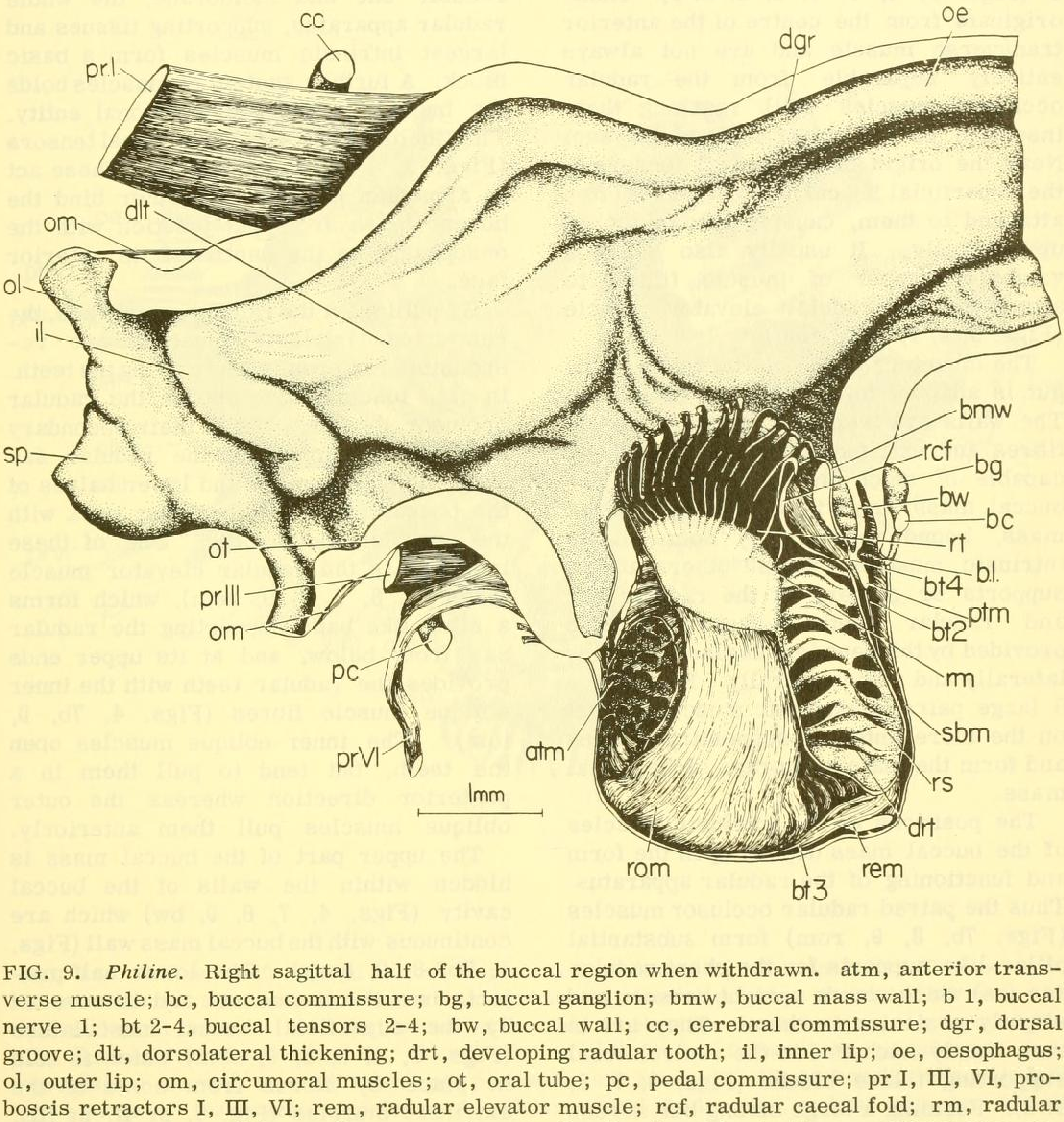

FIG. 9. *Philine.* Right sagittal half of the buccal region when withdrawn. atm, anterior transverse muscle; bc, buccal commissure; bg, buccal ganglion; bmw, buccal mass wall; b 1, buccal nerve 1; bt 2-4, buccal tensors 2-4; bw, buccal wall; cc, cerebral commissure; dgr, dorsal groove; dlt, dorsolateral thickening; drt, developing radular tooth; il, inner lip; oe, oesophagus; ol, outer lip; om, circumoral muscles; ot, oral tube; pc, pedal commissure; pr I, III, VI, proboscis retractors I, III, VI; rem, radular elevator muscle; rcf, radular caecal fold; rm, radular membrane; rom, radular occlusor muscle; rt, functional radular tooth; rs, radular sac; sp, sensory palp; sbm, superficial buccal musculature.

to the posterior aspect of the anterior transverse muscles and the supporting tissue (st 1) are blocks of a similar support (Figs. 4, 7, 8, st 2), forming the base for attachment of the large radular occlusor muscles (Figs. 7b, 8, 9, rom). These are paired, although their fibres intermingle at the anterior end. They form a support for the radular sac and insert widely on the outer side of the radular membrane (Figs. 7b, 9, rom, rm), each also sending a branch to insert on the radular sac. Running centrally between the radular occlusor muscles in an anteroposterior direction are the buccal tensors 3 (Figs. 3, 4, 5, 7, 8, 9, bt 3). These originate from the centre of the anterior transverse muscle and are not always entirely separable from the radular occlusor muscles until reaching their insertion on the tip of the radular sac. Near the origin of the buccal tensors 3, the superficial buccal musculature is often attached to them, causing it to be tucked up ventrally. It usually also sends a variable number of muscle fibres to attach to the radular elevator muscle (Figs. 3, 4, 9, sbm, rem).

The structure of the buccal region of the gut is adapted for the method of feeding. The walls are well provided with muscle fibres and extrinsic musculature and are capable of much change in shape. The buccal mass itself is a firm egg-shaped mass, bound together by some of its intrinsic muscles, whilst others act as supports or movers of the radular sac and radular teeth. Support is also provided by thickened areas placed ventrolaterally and anterolaterally. Four of the 6 large pairs of extrinsic muscles insert on the more anterior supporting tissues and form the main anchorage of the buccal mass.

The positions of the intrinsic muscles of the buccal mass depend upon the form and functioning of the radular apparatus. Thus the paired radular occlusor muscles (Figs. 7b, 8, 9, rom) form substantial pillar-like supports for the short radular sac (rs) which stands upright between and slightly posterior to them. They are in turn firmly anchored to the ventrolateral supporting tissue blocks (Figs. 4, 7, 8, st 2). Forming a large strong bar across the anterior end of the buccal mass is the anterior transverse muscle (Figs. 8, 9, atm). It presses into the concave anterior faces of the radular occlusor muscles along its length, and at its ends enters the anterolateral supporting tissue blocks (Figs. 4, 8, st 1). Since the anterolateral and ventrolateral supporting tissues are bound together both ventrally and posteriorly via the posterior transverse muscle (Figs. 4, 7, 8, 9, ptm), whilst the radular occlusor muscles insert on the radular sac and membrane, the whole radular apparatus, supporting tissues and largest intrinsic muscles form a basic block. A further system of muscles holds the buccal mass as a functional entity. This includes the 4 pairs of buccal tensors (Figs. 3, 4, 7, 8, 9, bt 1-4). These act in a median plane and together bind the buccal mass from its junction with the oesophagus to the centre of its anterior face.

By pulling on the radular membrane, the remaining intrinsic muscles are responsible for opening and moving the teeth. In this function they oppose the radular occlusor muscles, but in their secondary function of supporting the radular sac and holding the upper and lower halves of the buccal mass together they work with the radular occlusors. One of these muscles is the radular elevator muscle (Figs. 3, 6, 7, 8, 9, rem), which forms a sling-like band supporting the radular sac from below, and at its upper ends provides the radular teeth with the inner oblique muscle fibres (Figs. 4, 7b, 9, iom). The inner oblique muscles open the teeth, but tend to pull them in a posterior direction whereas the outer oblique muscles pull them anteriorly.

The upper part of the buccal mass is hidden within the walls of the buccal cavity (Figs. 4, 7, 8, 9, bw) which are continuous with the buccal mass wall (Figs. 4, 7b, 8, 9, bmw). The lower half projects into the haemocoel and is covered by the superficial buccal musculature (Figs. 3, 4, 5, 8, 9, sbm) which is held in place by fibres from some of the extrinsic muscles (Fig. 5, pr II, pr III).

When the proboscis is protruded, the buccal mass appears outside the body as a firm cylinder forming the ventral part of the proboscis (Fig. 1, stage 7, vp). The proboscis is produced by the rolling inside-out of the oral tube, buccal wall and the extreme anterior end of the oesophagus (Fig. 1, stages 2-7, ot, bw, oe). It is thus technically not a true

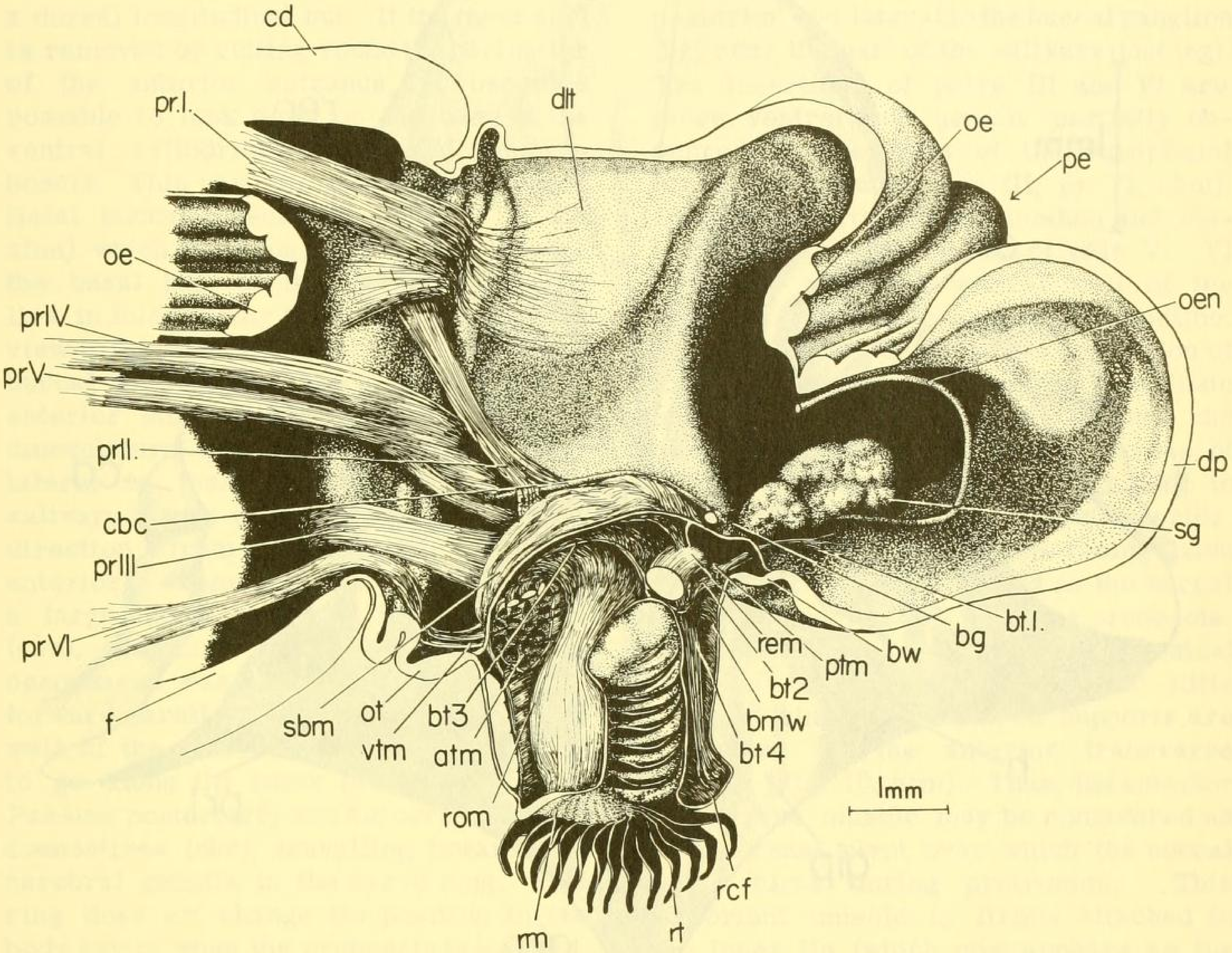

FIG. 10. *Philine.* Left sagittal half of the proboscis and anterior part of the body. The nerve ring is not shown. atm, anterior transverse muscle; bg, buccal ganglion; bmw, buccal mass wall; bt 1-4, buccal tensors 1-4; bw, buccal wall; cbc, cerebrobuccal connective; cd, cephalic disc; dlt, dorsolateral thickening; dp, dorsal part of proboscis; f, foot; oe, oesophagus; oen, oesophageal nerve; ot, oral tube; pe, proboscis entrance; pr I-VI, proboscis retractors I-VI; ptm, posterior transverse muscle; rcf, radular caecal fold; rem, radular elevator muscle; rm, radular membrane; rom, radular occlusor muscle; rt, functional radular tooth; sbm, superficial buccal musculature; sg, salivary gland; vtm, ventral tensor muscle.

proboscis, but an extrovert. Its dorsal part (Fig. 1, stage 7; Fig. 10; dp) is large and swollen, of variable shape. It has an anterior entrance (Figs. 1, 10, 11, pe) leading to the oesophagus at a point normally (i.e. when the proboscis is withdrawn) posterior to the buccal cavity. At the proboscis entrance the oesophageal walls turn inside out to help form the wall of its dorsal part. Posterior to the turning point, the oesophagus remains as a tube enclosed within the proboscis (Figs.

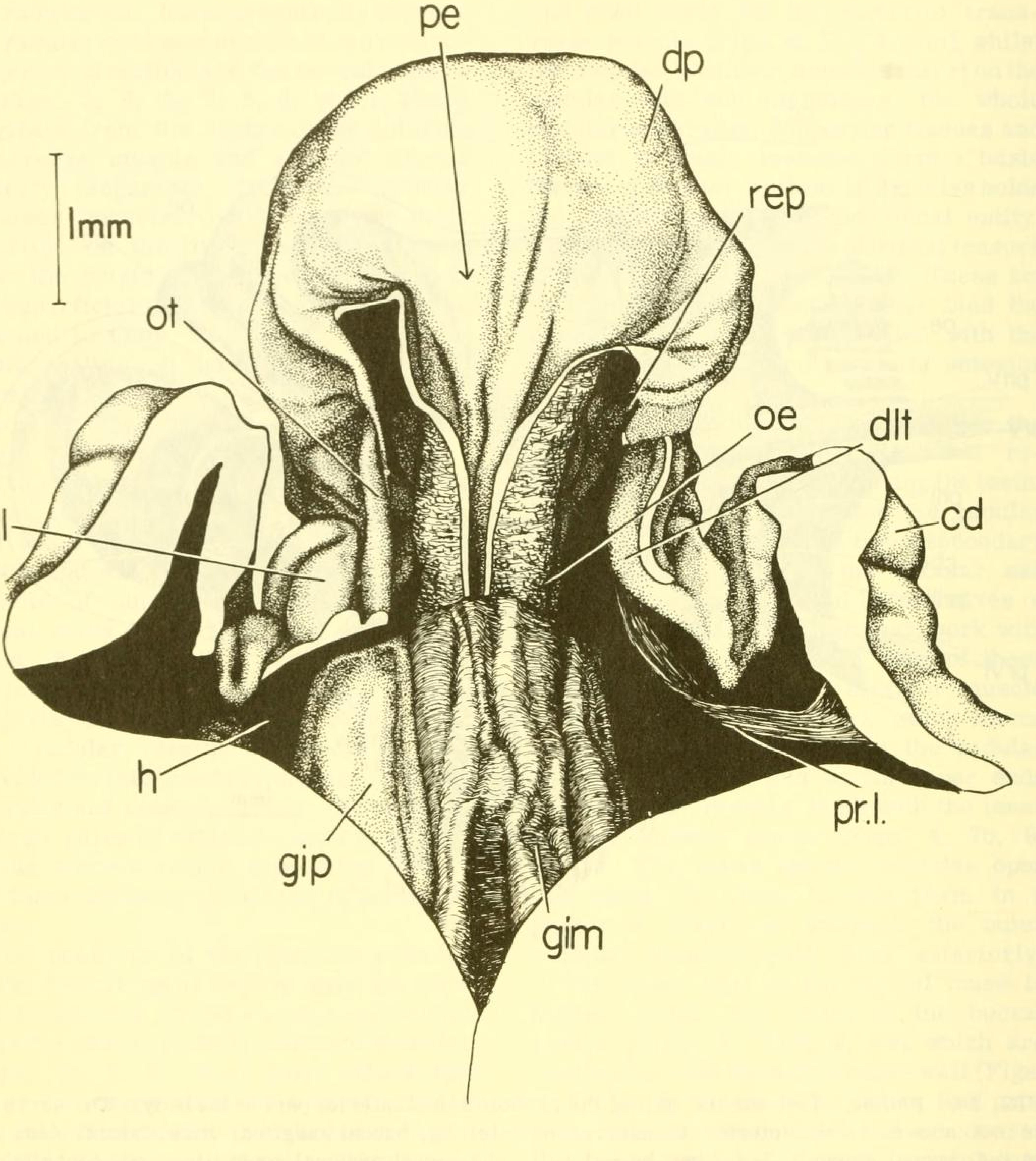

FIG. 11. *Philine.* Dorsal view of proboscis opened dorsally with a median longitudinal cut. The cephalic disc has also been opened mid-dorsally. cd, cephalic disc; dlt, dorsolateral thickening; dp, dorsal part of proboscis; gim, gizzard muscle; gip, gizzard plate; h, haemocoel; il, inner lip; oe, oesophagus; ot, oral tube; pe, proboscis entrance; pr I, proboscis retractor I; rep, reproductive system.

10, 11, oe). The turning point has no exact position but depends on the degree of protrusion. A few animals have been found in which the gizzard had partially or completely entered the dorsal part of the proboscis. In these cases, which were unusual, the turning point and proboscis entrance were as far back as the oesophagus would permit. Quite often some of the anterior coils of the reproductive system had entered the proboscis (Fig. 11, rep). The gizzard does not usually pass through the mouth.

The inner and outer parts of the oesophagus may be displayed together (as in Fig. 11) by opening the proboscis with a dorsal longitudinal cut. If the inner part is removed by cutting round the perimeter of the anterior entrance, it becomes possible to look down on the base of the ventral cylindrical portion of the proboscis. This part is covered by the superficial buccal musculature (Figs. 10, 12, sbm) which is no longer stretched around the basal half of the buccal mass, but lies in folds hiding the latter from dorsal view within the proboscis (Fig. 12a). The buccal ganglia can be seen on the now anterior edge of the superficial buccal musculature (bg, sbm). Approximately lateral to them on each side are the salivary glands (sg) trailing in an anterior direction from their ducts. Running anteriorly from each buccal ganglion is a large nerve supplying the oesophagus (oen), now much more taut than when the oesophagus was not protruded. They run forward parallel to the stretched anterior wall of the proboscis before turning back to go along the inner oesophageal tube. Passing posteriorly are the cerebrobuccal connectives (cbc), travelling towards the cerebral ganglia in the nerve ring. This ring does not change its position in the body cavity when the proboscis is everted. All the above-mentioned structures may also be seen in lateral view in sagittal section (Fig. 10).

With the exception of retractors IV and V the branches of the columellar muscle still lie within the main body cavity (Fig. 12a, lcm, mcm). The paired proboscis retractors IV and V (Figs. 10, 12a, pr IV, pr V), however, are now much elongated, and pass through the nerve ring to reach their insertions in the proboscis lateral to the folded superficial buccal musculature (sbm). Proboscis retractors IV terminate in the more anterior position. The insertions of all the extrinsic muscles are now anterior to their origins and are within the cavity of the proboscis. This enables them to act efficiently as proboscis retractors when necessary. Pair I inserts widely on the proximal dorsolateral walls of the proboscis (pr I, dlt), pair II immediately anterior to the insertion of IV and hence posterior and lateral to the buccal ganglion (bg) near the exit of the salivary duct (sg). The insertions of pairs III and VI are more ventral and usually partially obscured by the folds of the superficial buccal musculature (pr III, pr VI, sbm). Pair III inserts slightly median and posterior to the insertions of pair V; VI joins the proximal ventral wall of the proboscis on either side of the midline. Thus, whereas when the buccal region of the gut was withdrawn, the extrinsic muscles II, IV, V and III entered the buccal wall in lateral vertical areas of thickening, they now lie on each side in an oblique line with pair II most anterior. The vertical areas of thickening have thus become tipped forward as the buccal walls turned inside out in the proboscis. The distance between the most ventral part of the areas has remained little changed since these paired supports are connected by the anterior transverse muscle (Fig. 10, atm). Thus, the anterior transverse muscle may be considered as a horizontal pivot over which the buccal mass turns during protrusion. This important muscle is firmly attached to the inner lip (which now appears as the proximal rim of the proboscis) by the ventral tensor muscles (Fig. 10, vtm). These have an extremely important tensor function as the main anchor for the cumbrous ventral part of the proboscis. Proboscis retractors VI help in this function (Fig. 10).

The intrinsic musculature of this ventral part cannot be seen dorsally from within the cavity of the proboscis until the barrier of the superficial buccal musculature is removed, as in Fig. 12b. The interior of the buccal mass is thus revealed in a morphologically ventral view. Most obvious are the large areas of supporting tissue (Fig. 12b, st 2) to right and left. Between them are the buccal tensors 3 (bt 3) joining the radular sac (rs) anteriorly and disappearing posteriorly

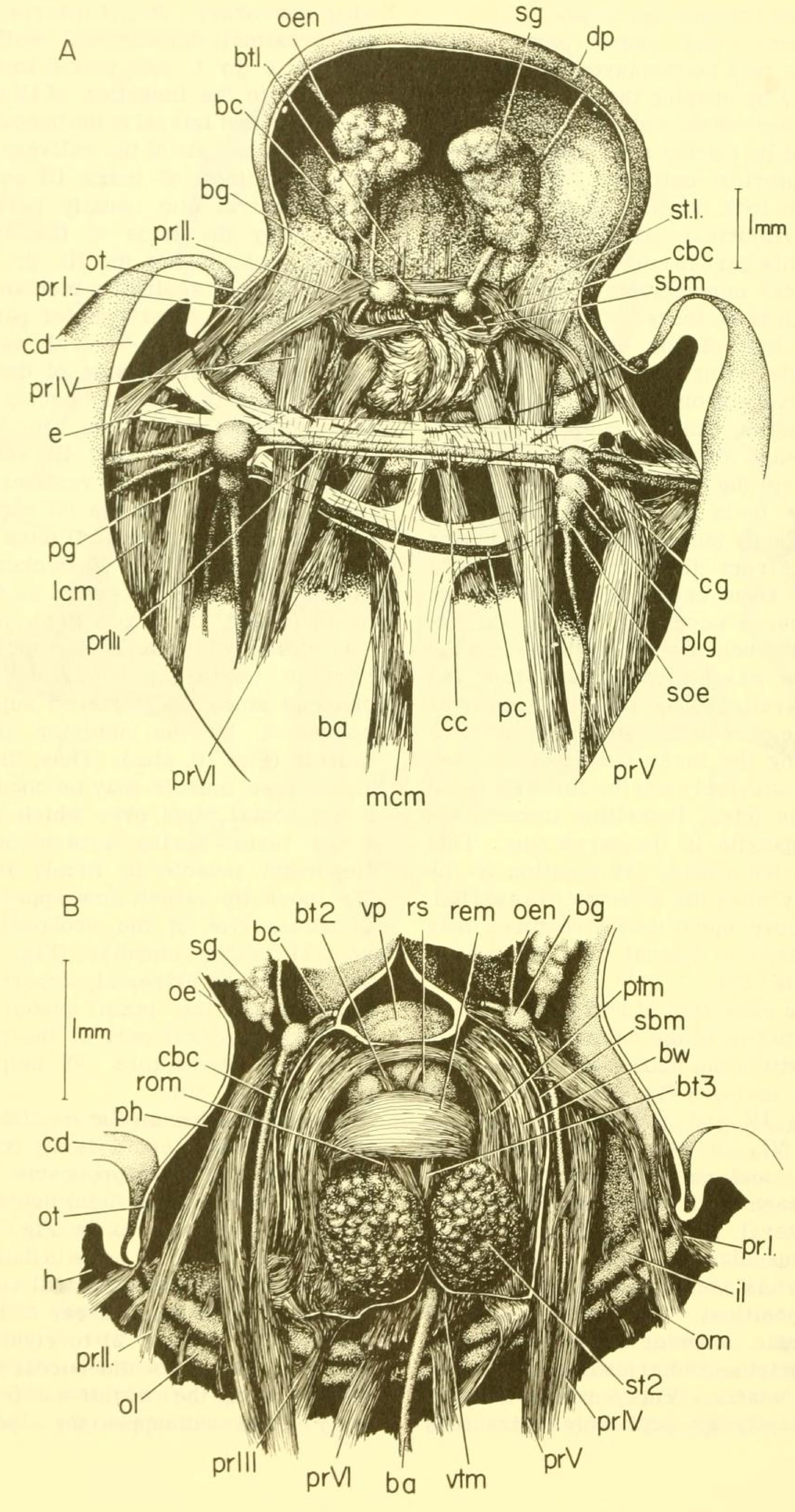
A
oen
sg
dp
btl.
bc
bg
st.l.
lmm
prII.
cbc
ot
sbm
prI.
cd
prIV
e
pg
lcm
prIIi
cg
plg
soe
ba
cc
pc
prVI
prV
mcm
B
bt2
vp
rs
rem
oen
bg
bc
sg
ptm
oe
lmm
sbm
cbc
bw
rom
bt3
ph
cd
ot
pr.I.
h
il
om
prII.
ol
st2
prIV
prIII
prVI
ba
vtm
prV

amongst the fibres of the anterior transverse muscle. The last is now posterior to the rest of the buccal mass, and all the intrinsic musculature is similarly inverted due to the 180^o turn which the buccal mass has undergone in protrusion. It has changed from an upright position, crowned with the functional radular teeth, within the buccal cavity, to lie upside down outside the buccal and main body cavities with the teeth projecting ventrally. This change can best be explained by reference to the sagittal sections (Figs. 9, 10).

Whilst within the buccal cavity, the upper half of the buccal mass was covered by the buccal mass wall, but its lower part was covered by the superficial buccal musculature. When it is protruded as the ventral part of the proboscis, the buccal mass wall covers the major part of the buccal mass. Basally and proximally, however, it is now covered by the buccal wall (Fig. 13, a-b, c-d). This has become possible since in protrusion the fold between buccal and buccal mass walls (which had enclosed a narrow space around the buccal mass [p 286]) is straightened out as the buccal wall turns inside out. Since the superficial buccal musculature is attached dorsal to this fold, it is not only relieved of its former function of enclosing the lower half of the buccal mass, but its edges are not pulled down into the ventral part of the proboscis. Since the buccal mass wall (together with the inner and outer oblique muscles) is stretched downwards in the fully protruded proboscis, the radular membrane is opened to form a very wide V (Fig. 13d, rm). The teeth thus fan out around the distal edge of the buccal mass (Fig. 1, 10, rt). They can be closed only when partial retraction of the buccal mass occurs - for instance, by contraction of the centrally placed radular occlusor muscles.

3. INNERVATION OF THE BUCCAL REGION AND OF THE ANTERIOR REGIONS OF THE BODY

The nerve supply of the buccal region and neighbouring parts has been studied by dissection of unstained preserved animals and by intravitam staining with oxidized methylene blue and leucobase methylene blue as prepared by Smith (1946). The silver staining method of Alexandrowicz (1960) was not as succussful for tracing fine nerves as methylene blue reduced with Rongalit white. For studying the innervation of the intrinsic musculature of the gut walls and buccal mass, the buccal region of the gut was observed after the method of Alexandrowicz (1932).

In a specimen of *Philine* with the proboscis in, the nerve ring surrounds the

FIG. 12. *Philine*. 12a: dorsal view of proboscis and anterior part of body cut open mid-dorsally as in Fig. 11. Here a larger part of the dorsal wall of the proboscis has been removed and also the inner part of the oesophagus.

12b: a subsequent dissection with only the ventral part of the proboscis shown. The intrinsic muscles of the buccal mass are revealed by removal of the superficial buccal musculature. A longitudinal cut has been made in the mid-ventral part of the oesophagus and buccal wall. Through this cut the most ventral, undissected region of the proboscis may be seen.

ba, buccal artery; bc, buccal commissure; bg, buccal ganglion; bt 1-3, buccal tensors 1-3; bw, buccal wall; cbc, cerebrobuccal connective; cc, cerebral commissure; cd, cephalic disc; cg, cerebral ganglion; dp, dorsal part of proboscis; e, eye; h, haemocoel; il, inner lip; lcm, lateral columellar muscle; mcm, median columellar muscle; oe, oesophagus; oen, oesophageal nerve; ol, outer lip; om, circumoral muscles; ot, oral tube; pc, pedal commissure; pg, pedal ganglion; ph, proboscis haemocoel; plg, pleural ganglion; pr I-VI, proboscis retractors I-VI; ptm, posterior transverse muscle; rem, radular elevator muscle; rom, radular occlusor muscle; rs, radular sac; sbm, superficial buccal musculature; sg, salivary gland; soe, supra-oesophageal ganglion; st 1, 2, supporting tissues 1, 2; vp, ventral part of proboscis; vtm, ventral tensor muscle.

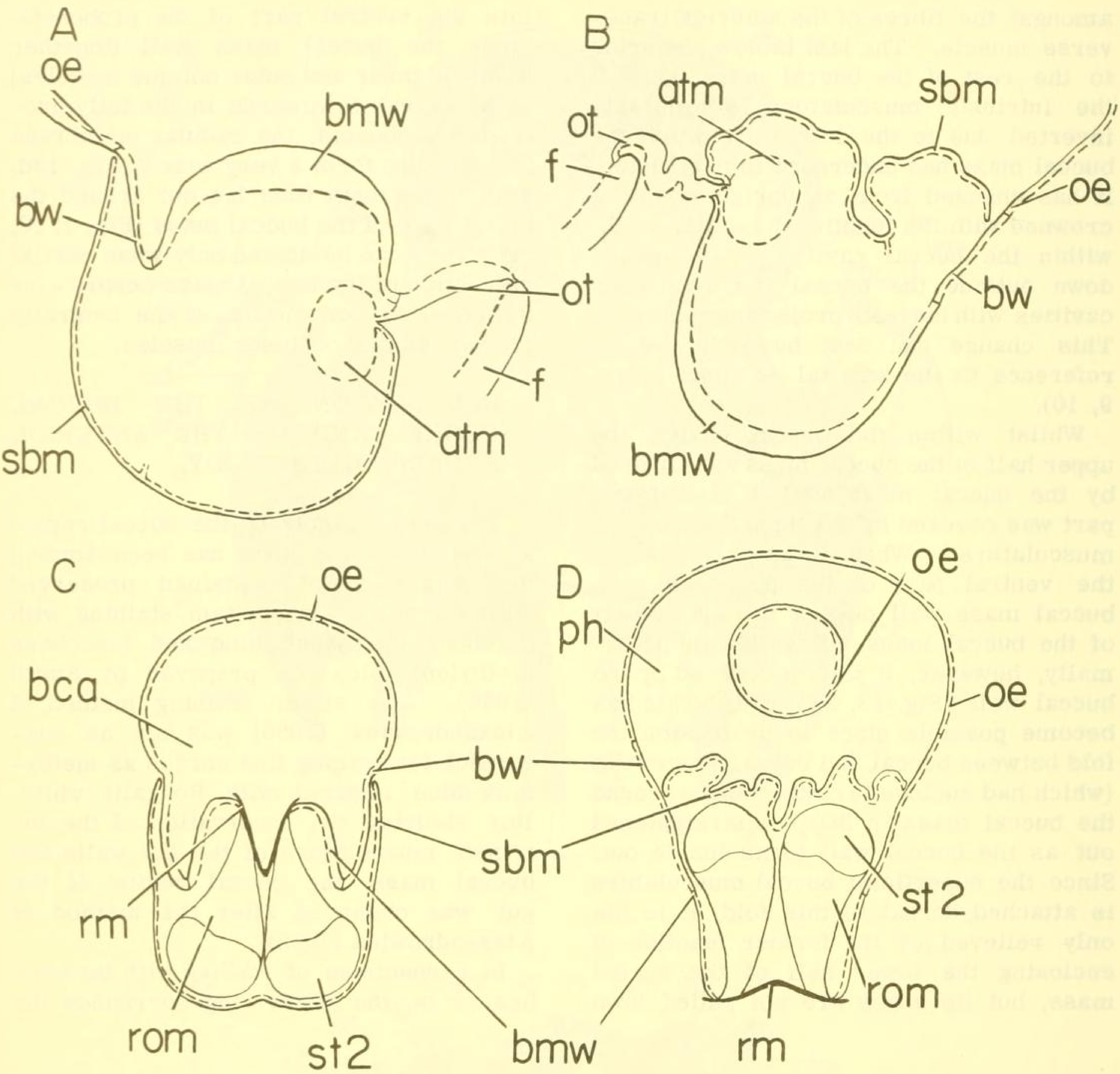

FIG. 13. *Philine.* Diagrams to show the changes in position of the walls of the buccal region when the proboscis is protruded. In all, the morphological inner side of the gut wall is shown with a dashed line. The first two (a, b) are longitudinal sections through the buccal mass, with only the anterior transverse muscle and walls in situ. The second two (c, d) are transverse sections of the buccal region through the supporting tissues st 2. Only the radular membrane and radular occlusor muscles are shown in the buccal mass. In each pair the left diagram shows the proboscis withdrawn, the right, the proboscis protruded. atm, anterior transverse muscle; bca, buccal cavity; bmw, buccal mass wall; bw, buccal wall; f, foot; oe, oesophagus; ot, oral tube; ph, proboscis haemocoel; rm, radular membrane; rom, radular occlusor muscle; sbm, superficial buccal musculature; st 2, supporting tissue 2.

oral tube and the extrinsic muscles joining it, whereas when the proboscis is protruded, the nerve ring encircles the oesophagus.

The cerebral ganglia innervate the anterior sensory areas, the oral tube, part of the anterior body wall and muscle fibres in the walls of the anterior blood sinuses. Nerves leave the pedal ganglia for the ventral sensory patches, the foot, branches of the columellar muscle and the muscular walls of the anterior blood sinuses. The buccal ganglia innervate extrinsic muscles I, II, III and IV, the walls of the buccal region of the gut, together with the oesophagus and the intrinsic musculature of the buccal mass.

The cerebral ganglia and nerves

Thirteen nerves leave each cerebral ganglion. Of these, 7 nerve roots supply organs direct, whilst 6 lead to commissures and connectives. Besides being joined by the large cerebral commissure (Figs. 5, 9, 12a, 14, 15, cc) dorsal to the gut, the cerebral ganglia are linked by a very small commissure (Fig. 15, cc2) travelling ventral to the oral tube adjacent to the pedal commissure.

The large cerebral commissure (Figs. 14, 15, cc) leaves from an anterodorsal position whilst the smaller (cc2) has an anteroventral root. Both leave from the inner side of the ganglion. From near the base of cc2 leaves cerebral nerve 6 (Figs. 14, 15a, 16, 17a, c6), a tiny nerve which soon divides to 2 parts, one supplying the oral tube ventrally, whilst the other branches to supply fibres of retractor III and the median columellar muscle (mcm) where they interweave at their insertions.

Also leaving the inner anteroventral face of the ganglion from a point slightly anterior and dorsal to cc2 is the cerebrobuccal connective (Figs. 14, 17a, cbc). This runs to the corresponding buccal ganglion enclosed in a thin sheath with pedal nerve 9 (p 9) which accompanies it as far as the insertions of retractor muscles IV and V together with the few fine strands of muscle described earlier (p 289; Fig. 5) linking the latter to the lateral columellar muscle.

The main cerebropleural connective leaves the posterior face of the cerebral ganglion, (Figs. 14, 15, cg, plg) whilst the larger cerebropedal connective (Figs. 14, 15, cpc) leaves mid-ventrally. The second cerebropedal connective (Fig. 15, cpc2) has a double root from the bases of c5 and c7. The 2 fine branches join shortly and travel close to the outer surface of the cerebral ganglion as one small connective, together with some muscle fibres, eventually reaching the posterodorsal face of the pedal ganglion. This connective is described by Vayssière (1880) in *Gastropteron* and *Philine* and as typical of tectibranchs in general. The statocyst on the dorsal surface of the pedal ganglion is innervated from the cerebral ganglion as described by Lacaze-Duthiers (1872). The nerve responsible for this is the small c9 (Fig. 15).

The remaining cerebral nerves leave the outer face of each ganglion to travel either above or below the inner branch of the lateral columellar muscle (Figs. 14, 15, 16, c1, c2, c3, c4, c5, c7, c8, lcm, ilc). On each side this branch is large and runs very close to the ganglion. The eye rests on a few of its fibres (Fig. 12a, 3) and is supplied by a fine nerve (Figs. 14, 15, 16, c4) which takes a very meandering course in contracted specimens. Nerve c4 leaves from a point dorsal to the lateral columellar muscle. The roots of c3 and c7, sometimes united, are very near to its base (Figs. 14, 15, 16, c3, c7). Nerve c3 is the more dorsal and divides to 2 parts both of which supply the cephalic disc. This nerve runs very close to the anterior sinus sac wall (Fig. 14, c3, as). Its larger branch enters the muscle layers of the body wall just posterior to this sinus and eventually runs back to the posterior tip of the cephalic disc. The smaller branch enters more anteriorly and runs deeper. Nerve c7 leaves the cerebral ganglion parallel to nerve c2 below it (Figs. 14, 15, c7, c2). Both travel towards Hancock's organ, the most anterior part of which is supplied by c1, a huge nerve which leaves the outer ventral face of the cerebral ganglion and dives down median and ventral to the inner branch of the lateral columellar muscle (Figs. 14, 15, 16, c1, lcm, ilc). The innervation of Hancock's organ is thus similar to the figure given by Guiart (1901).

Nerves c5 and c8 are more dorsal.

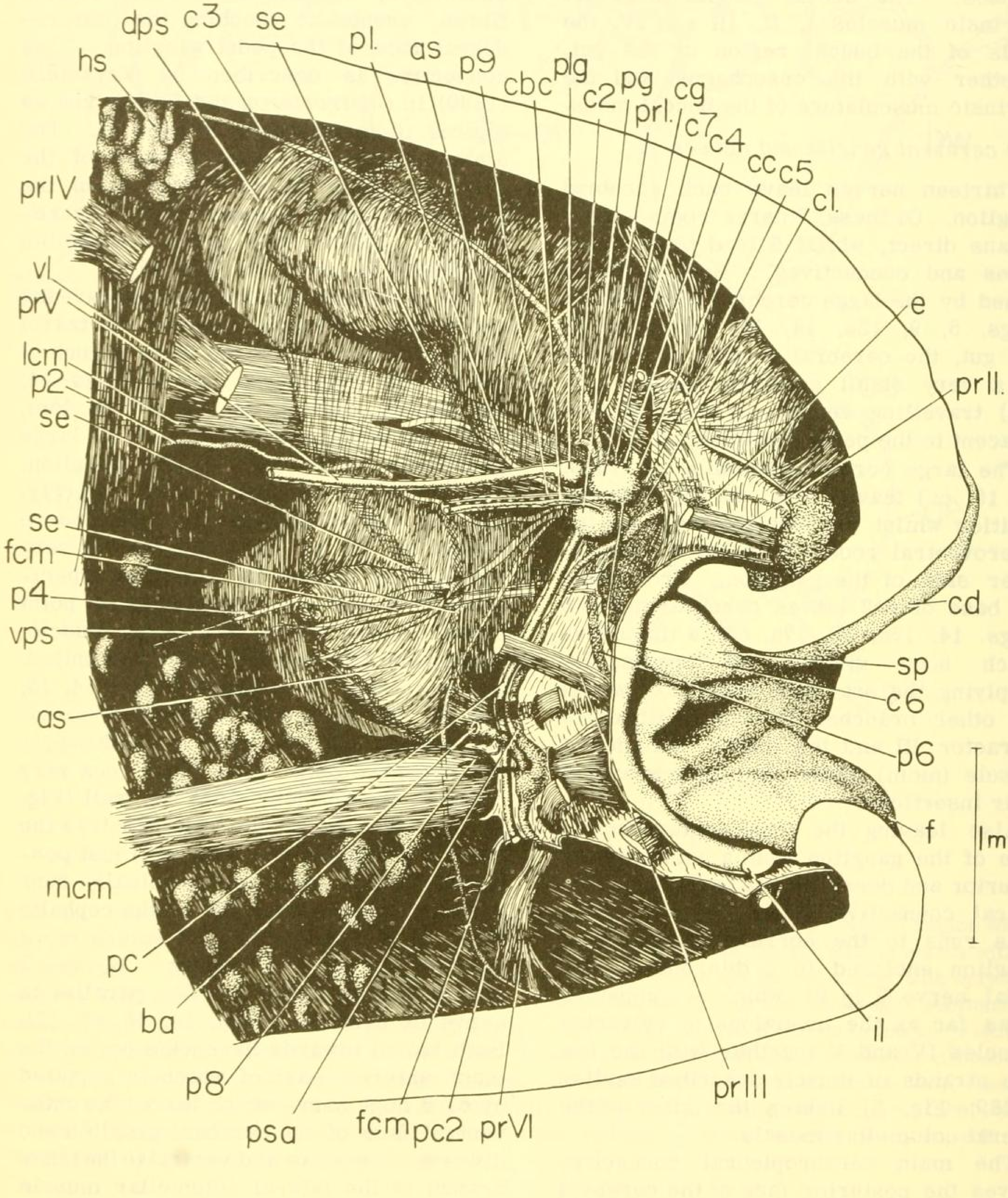
dps
c3
se
hs
pl.
as
p9
cbc
plg
c2
pg
cg
prl.
c7
c4
cc
c5
cl.
prIV
vl
prV
lcm
p2
se
e
prII.
se
fcm
p4
vps
cd
sp
c6
as
p6
f
1mm.
mcm
pc
ba
il
p8
prIII
psa
fcm
pc2
prVI

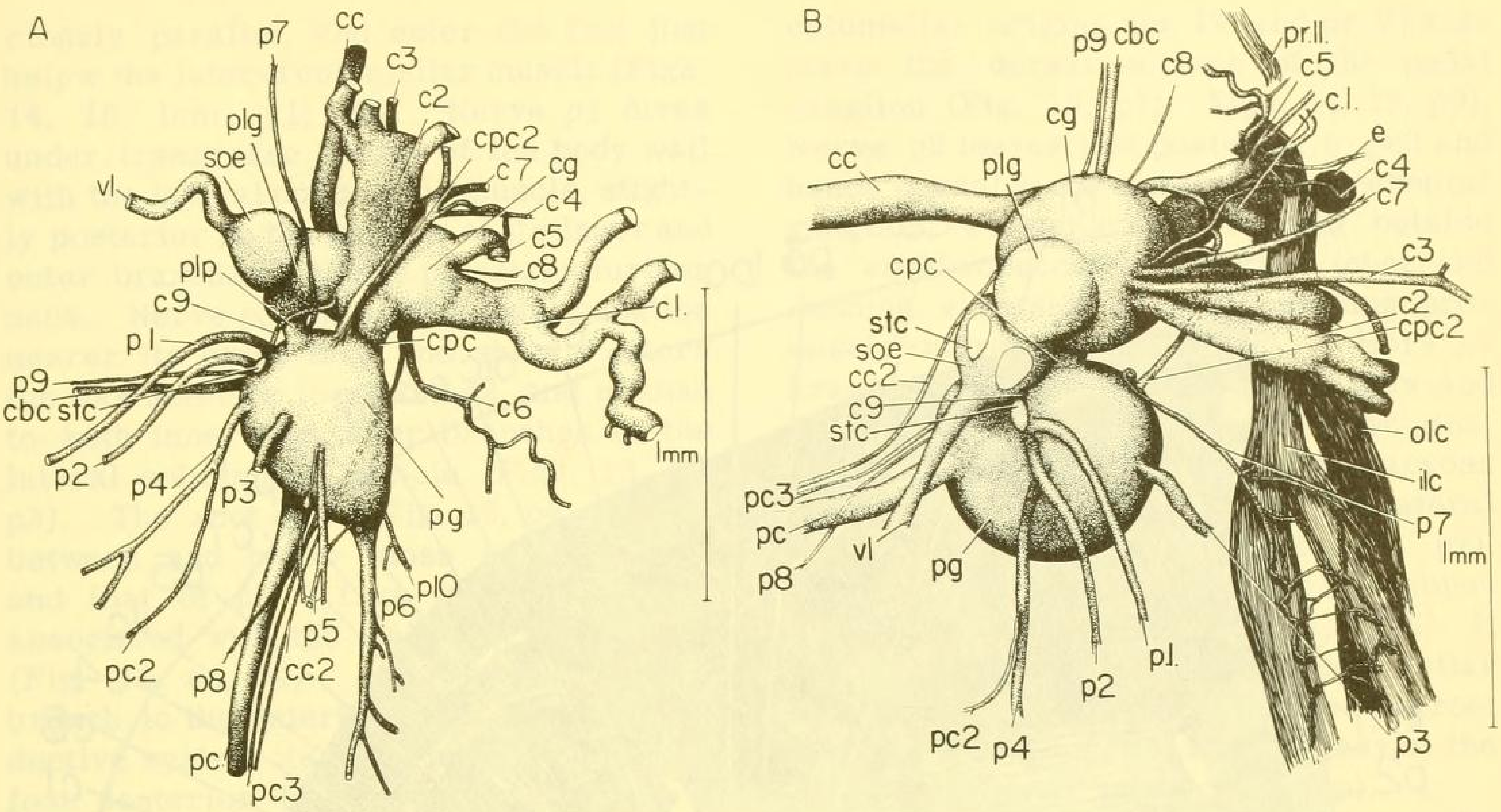

FIG. 15. ***Philine.*** The ganglia on the right side of the nerve ring: a, in ventrolateral view with the proboscis withdrawn; b, in posterior view with the proboscis out. c 1-9, cerebral nerves 1-9; cbc, cerebrobuccal connective; cc, cc2, cerebral commissures 1, 2; cg, cerebral ganglion; cpc, cpc2, cerebropleural connectives 1, 2; e, eye; ilc, inner branch of lateral columellar muscle; olc, outer branch of lateral columellar muscle; p 1-10, pedal nerves 1-10; pc, pc2, pc3, pedal commissures 1, 2, 3; pg, pedal ganglion; plg, pleural ganglion; plp, pleuropedal connective; prII, proboscis retractor II; soe, supra oesophageal ganglion; stc, statocyst; vl, visceral loop.

Nerve c8 is very fine and divides amongst the fibres of retractor muscle pr I where they insert in the cephalic disc. Nerve c5 has a stout basal part from which part of the second cerebropedal connective leaves proximally, whilst distally 3 nerves depart for anterior destinations. The first divides finely in the anterior part of the cephalic disc; the second travels more deeply and eventually branches many times to supply the dorsal sensory patch and the surrounding area; the third gives one branch passing amongst the inserting fibres of the lateral columellar muscle, and another to the rim of the oral tube.

The pedal ganglia and nerves

Fourteen nerves leave each pedal ganglion including 3 pedal commissures and 3 connectives (Fig. 15). Four of the pedal nerves leave the posterior face (Figs. 14, 15, p1, p2, p3 and p4). Nerves p1 and p2 are sometimes joined at their bases, which lie immediately adjacent to the statocyst on the posterodorsal surface of the ganglion. They run back, at first

FIG. 14. ***Philine.*** Left sagittal half of the body with gut removed posterior to the inner lip. as, anterior sinus; ba, buccal artery; c 1-7, cerebral nerves 1-7; cbc, cerebrobuccal connective; cc, cerebral commissure; cd, cephalic disc; cg, cerebral ganglion; dps, dorsal posterior sinus; e, eye; f, foot; fcm, factor of columellar muscle; hs, haemal sac; il, inner lip; lcm, lateral columellar muscle; mcm, median columellar muscle; p 1, 2, 4, 6, 8, 9, pedal nerves 1, 2, 4, 6, 8, 9; pc, pc2, pedal commissures 1, 2; pg, pedal ganglion; plg, pleural ganglion; pr I-VI, proboscis retractors I-VI; psa, pedal sinus artery; se, septum; sp, sensory palp; vl, visceral loop; vps, ventral posterior sinus.

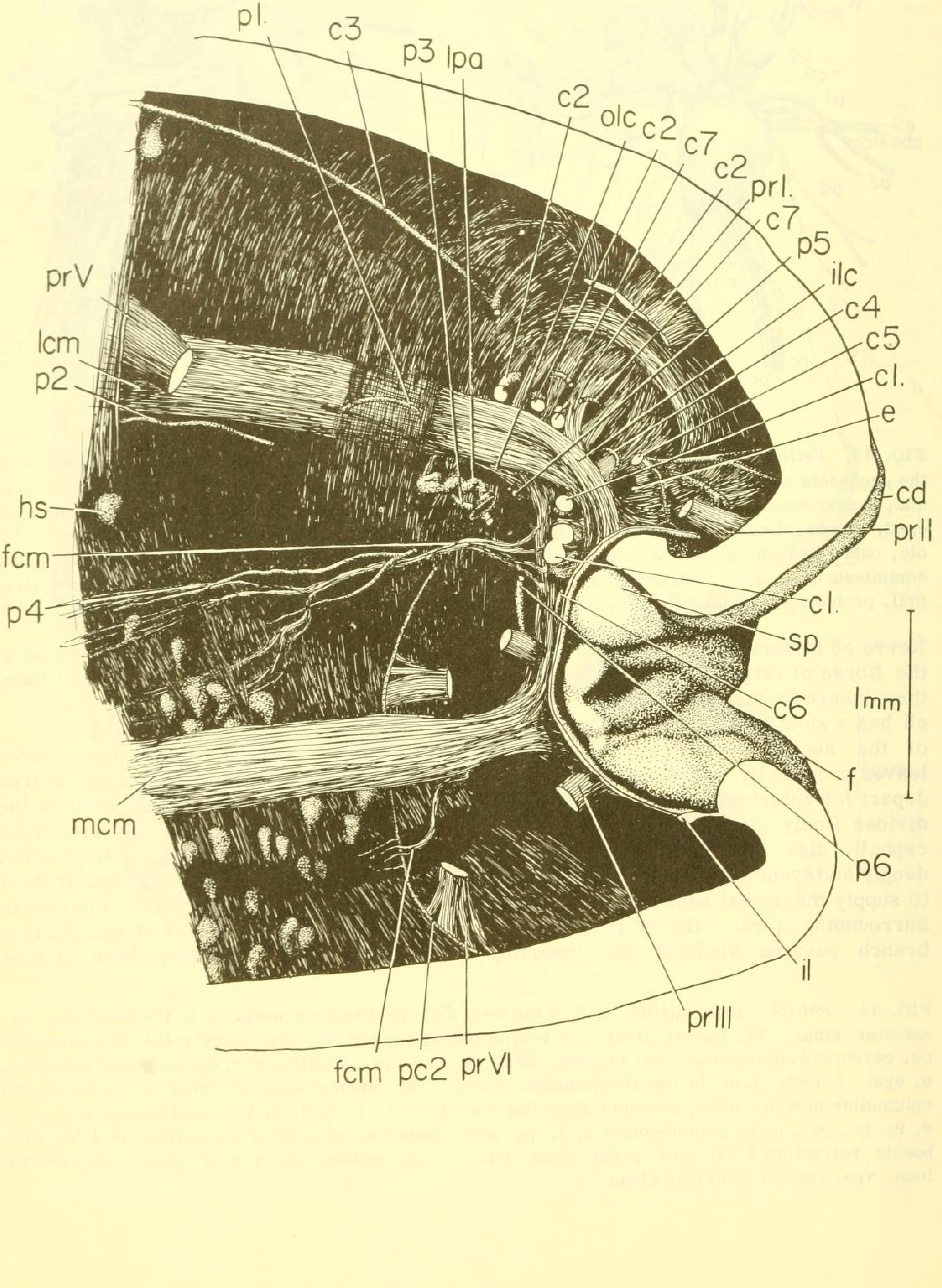
pl.
c3
p3
lpa
c2
olc
c2
c7
c2
prI.
c7
p5
ilc
c4
c5
cl.
e
cd
prII
cl.
sp
c6
1mm
f
p6
il
prIII
prV
lcm
p2
hs
fcm
p4
mcm
fcm
pc2
prVI

closely parallel, and enter the foot just below the lateral columellar muscle (Figs. 14, 16, lcm, p1, p2). Nerve p1 dives under transverse fibres of the body wall with the lateral columellar muscle, slightly posterior to the origins of its inner and outer branches. Nerve p2 enters further back. Nerve p3 leaves the pedal ganglion nearer its outer face and shortly enters the foot anterior to p1 and p2, and median to both inner and outer branches of the lateral columellar muscle (Figs. 15, 16, p3). The root of p4 (Fig. 15, p4) departs between and below those of p1 and p2 and that of p3. Like c3, it is closely associated with the wall of a blood sinus (Fig. 14, as, p4). After giving a small branch to the anterior coils of the reproductive system its main branch enters the foot posterior to the sinus. Where it enters, it divides around the inserting fibres of a small factor of the columellar muscle (Figs. 14, 16, p4, fcm). A thin inner branch of p4 travels across the foot in the surface layers to meet its opposite number and form an elongated parapedal commissure (Figs. 14, 15, 16, pc2). This commissure runs posterior to the origins of the proboscis retractors VI. From its centre 2 small branches enter the foot on either side of another factor of the columellar muscle (Figs. 14, 16, pc2, pr VI, fcm).

The commissure pc3 is even smaller (Fig. 15, pc3). It leaves the inner anterodorsal surface of the pedal ganglion and runs with cc2 adjacent to the large pedal commissure (pc) which has an anteroventral root. From near the base of pc3 on each side a tiny nerve p8 leaves for the median columellar muscle (Figs. 14, 15, p8). Similar small nerves p7 and p9 supplying the lateral columellar muscle and the proboscis retractors with columellar origins (pr IV and pr V) also leave the dorsal surface of the pedal ganglion (Fig. 15, p7; Figs. 14, 15, p9). Nerve p9 leaves just posterior to pc3 and bends dorsalwards median to the cerebral ganglion, subsequently crossing outside the cerebrobuccal connective (cbc) and running alongside it until reaching proboscis retractors IV and V. Here p9 branches to form a network across and between the 2 muscles near their origins. Nerve p7 forms a similar network across the anterior branches of the lateral columellar muscle (Fig. 15b, ilc, p7). Its root is between those of the 2 cerebropedal connectives (Fig. 15, cpc, cpc2). It passes towards the lateral columellar muscle median to cpc2. Between its root and the roots of p1 and p2 leaves the short pleuropedal connective (plp).

The remaining pedal nerves leave the outer surface of the pedal ganglion. The most anterior is the tiny p10 (Fig. 15a) which branches widely in the ventral suspension sheet of the sinus surrounding the main pedal commissure (pc1). It supplies the above-mentioned fibres of the columellar muscle (Figs. 17, 22, fcm) which insert lateral to muscle VI with the main branch of p4. Posterior to the root of p10 is the much larger one of p6 (Figs. 14, 15a, 16, p6). This nerve has several parts, the largest of which supplies the ventral sensory patch, the smaller ones innervating the anterior parts of the reproductive system, and the margin of the foot. From the base of p6 is a small connective running to p5. This nerve leaves the pedal ganglion posterior to p6 near to p3 (Fig. 15a, p5). It has several branches to the foot below Hancock's organ (Fig. 16, p5). There is usually a ganglionic swelling near the base of one of its smaller factors (Fig.

FIG. 16. *Philine.* Left sagittal half of the body with gut removed posterior to the lip. In dissection subsequent to Fig. 14, the sinuses and ganglia have been removed and the extrinsic muscles trimmed back. c 1-7; cerebral nerves 1-7; cd, cephalic disc; e, eye; f, foot; fcm, factor of columellar muscle; hs, haemal sac; il, inner lip; ilc, inner branch of lateral columellar muscle; lcm, lateral columellar muscle; lpa, left pedal artery; mcm, median columellar muscle; olc, outer branch of lateral columellar muscle; p 1-6, pedal nerves 1-6; pc2, pedal commissure 2; pr I-VI, proboscis retractors I-VI; sp, sensory palp.

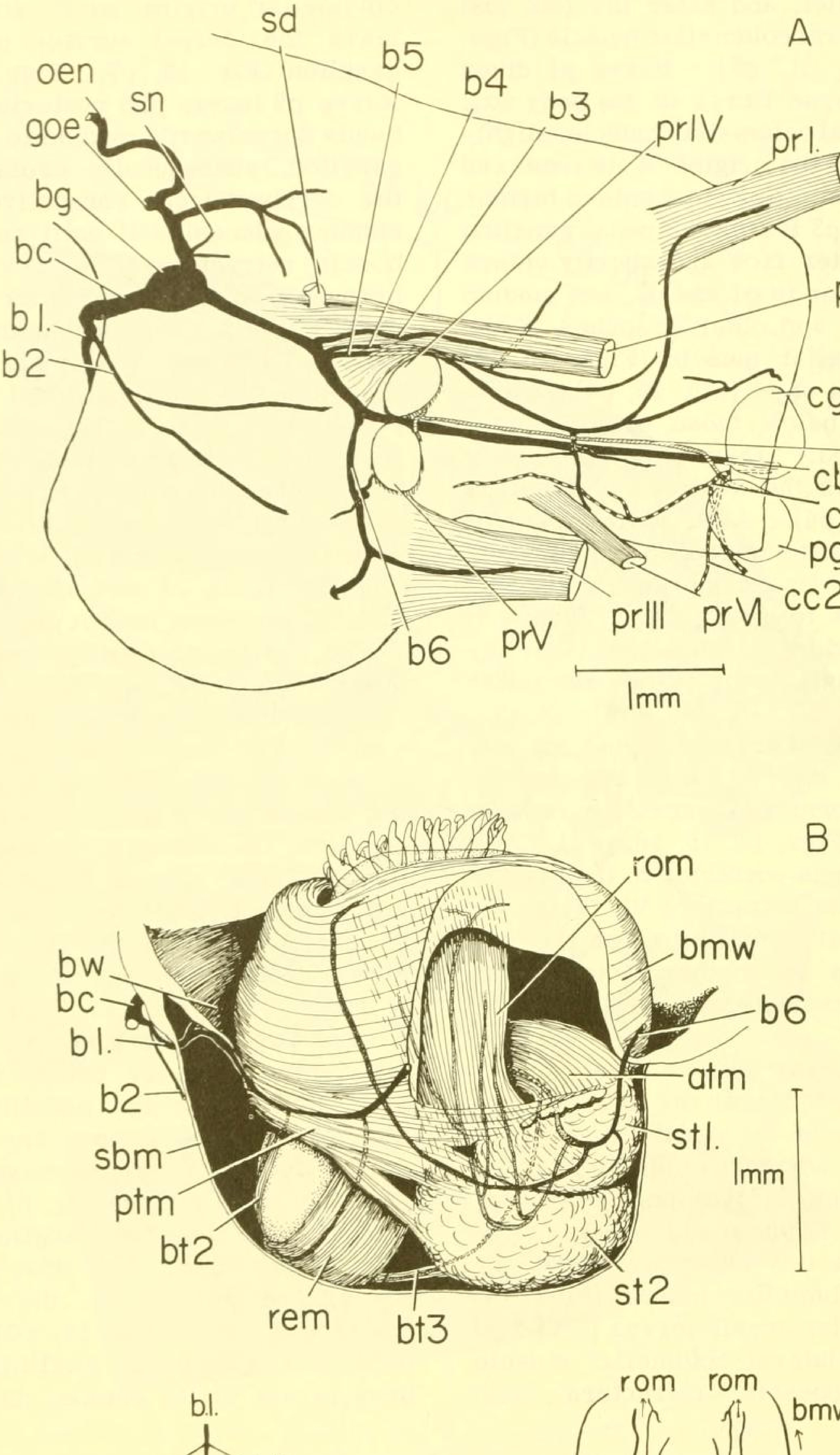
A
sd
oen
sn
goe
bg
bc
bl.
b2
b5
b4
b3
prIV
prI.
prII
cg
p9
cbc
c6
pg
cc2
prVI
prIII
prV
b6
lmm
B
rom
bmw
bw
bc
bl.
b2
sbm
ptm
bt2
rem
bt3
b6
atm
stl.
lmm
st2
bl.
b2
sbm
bw
bmw
bt2
rem
rom
rom
bmw
b6
b6
bc2
bt3

15a, p 5).

The buccal ganglia and nerves

The buccal ganglion of each side has 3 main nerves leaving it. The first leaves laterodorsally (Figs. 5, 7, 10, 12a, 17a, oen) and goes to the oesophagus, giving branches to the salivary gland (Fig. 17a, sn) and dorsolateral wall of the buccal region. It has been called the gastro-oesophageal nerve by Lacaze-Duthiers (1872). After these branches leave there is a small ganglionic swelling and the nerve then follows a meandering lateral course along the oesophagus. It is thus capable of spanning a greater distance when the proboscis is out and the oesophageal wall stretched. Such ganglionic swellings have been noticed in other opisthobranch molluscs. This one may be comparable to the gastro-oesophageal ganglion described by Russel (1929) as mainly confined to nudibranchs. However, Guiart (1901) has described gastro-oesophageal ganglia in the tectibranch *Gastropteron*.

The second nerve trunk leaves the buccal ganglion laterally. It is the common trunk of the cerebrobuccal connective and other nerves which branch off before the extrinsic muscles IV and V are reached (Fig. 17a, cbc, b3, b4, b5, b6). The latter nerves have been collectively called the pharyngeal nerve by Lacaze-Duthiers (1898). Nerves b3, b4 and b5 leave the nerve trunk almost together, going slightly dorsalwards, whilst b6 departs a little further along, immediately posterior to the insertions of muscles IV and V. Nerve b3 supplies muscle II which it enters almost immediately (b3, pr II), b4 bifurcates and innervates the dorsolateral wall of the oral tube (b4, ot), whilst b5, the largest of the 3, runs laterally giving branches to the oral tube and finally supplying muscle I and the oral rim (b5, ot, pr I). Nerve b6 goes ventrally away from the cerebrobuccal connective giving a branch to retractor III (Fig. 17, b6, cbc, pr III). It subsequently enters the buccal mass in the region of the supporting tissue (Fig. 17b, st 1) and, passing along the anterior transverse muscle (atm), unites with its partner from the other side. Thus a small buccal commissure is established (bc2). This commissure gives on each side a small branch to the buccal wall and a larger one dividing several times within the radular occlusor muscle (rom). A median nerve leaves to supply buccal tensor 3 (bt3).

The third nerve trunk leaving each buccal ganglion is the large buccal commissure (Figs. 5, 7a, 9, 10, 12b, 17, bc). From its centre leaves the important nerve b1 (Figs. 7a, 17, b1) supplying the remainder of the intrinsic muscles of the buccal mass. This is the radular nerve of Lacaze-Duthiers (1898) and the buccal nerve of Brown (1934). A pair of small nerves (Figs. 7a, 17, b2) leaves from near the base to supply the superficial buccal musculature. Shortly after their exit, b1 divides into 2 parts. Each runs diagonally outwards entering the pigmented buccal wall (bw) superficially, and near the posterior transverse muscle (ptm) gives a branch going ventrally to

FIG. 17. *Philine.* The innervation of the buccal region:
a, the nerves of the walls and extrinsic muscles shown in right lateral view;
b, the buccal mass dissected from the right side to a stage mid-way between Figs. 4 and 8, to show its nerve supply. The diagrams inset below show the branches of buccal nerve 1 in posterior view and those of buccal nerve 6 in anterior view. atm, anterior transverse muscle; b 1-6, buccal nerves 1-6; bc, bc2, buccal commissures 1, 2; bg, buccal ganglion; bmw, buccal mass wall; bt, 2, 3, buccal tensors 2, 3; bw, buccal wall; c 6, cerebral nerve 6; cbc, cerebrobuccal connective; cc2, cerebral commissure 2; cg, cerebral ganglion; goe, gastro-oesophageal ganglion; oen, oesophageal nerve; p 9, pedal nerve 9; pg, pedal ganglion; pr I-VI, proboscis retractors I-VI; ptm, posterior transverse muscle; rem, radular elevator muscle; rom, radular occlusor muscle; sbm, superficial buccal musculature; sd, salivary duct; sn, salivary nerve; st 1, 2, supporting tissues 1, 2.

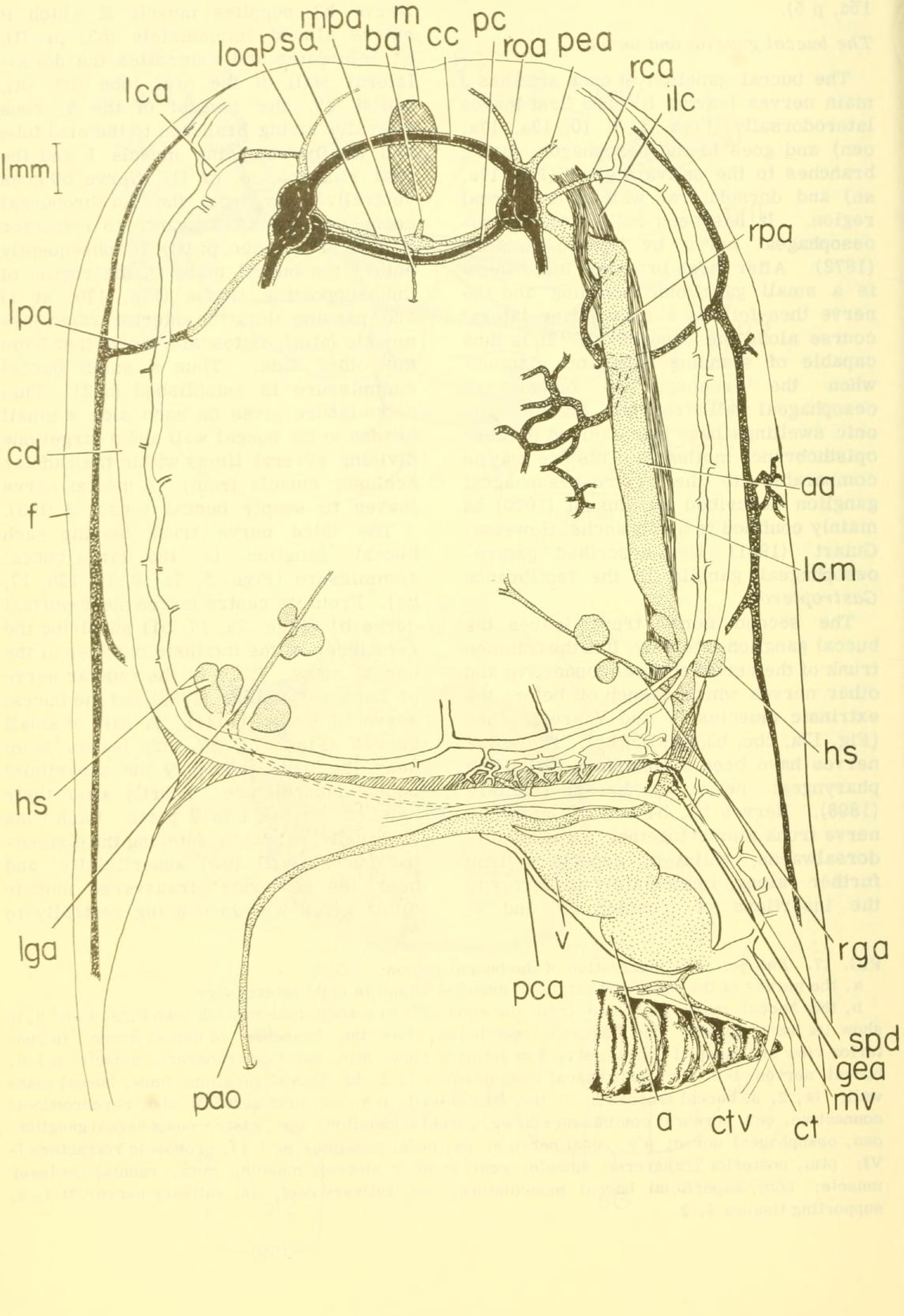
mpa
m
psa
ba
cc
pc
loa
roa
pea
rca
lca
ilc
lmm
rpa
lpa
cd
aa
f
lcm
hs
hs
lga
v
rga
pca
spd
gea
mv
pao
a
ctv
ct

the buccal tensor 2 (bt 2) and another to the radular elevator muscle (rem), continuing towards the supporting tissue (st 1) where the extrinsic retractor muscles II, III, IV and V insert.

4. THE BLOOD SYSTEM OF THE ANTERIOR REGIONS

The blood system has been studied by injecting it with dilute Nile blue. This method has met with some succes in both *Philine* and its larger relative *Scaphander lignarius* (Linn.). The blood system of *Philine*, however, has some interesting features which do not appear in *Scaphander*.

The heart of *Philine* lies to the right of the body, posterior to the diaphragm. The ventricle is anterior to the auricle (Fig. 18, v, a). The latter collects blood from the gill (ctv) and also from a network of vessels on the mantle roof. The mantle vessels (mv) enter in 2 main directions: from the anterior edge and from the lateral and posterior surfaces. Blood then passes into the ventricles, which it leaves by 2 large blood vessels, the anterior and posterior aortae (aa, pao). Brown (1934) described the course of these briefly. Pelseneer (1893) refered to a "glande sanguine" as an expansion of the aortic wall within the pericardium. It has not been investigated in the present study.

The posterior aorta (Fig. 18, pao) curves around the visceral mass, entering it deeply to supply the digestive gland, stomach, intestine and gonad. The anterior aorta (aa) goes across the floor of the pericardial cavity (pca) then gives a small blood vessel, the genital artery (gea), which shortly branches twice to supply the female genital duct and parts of the reproductive system within the visceral mass. The aorta then passes under the spermathecal duct (spd) at the right side of the body and below the visceral ganglion before turning towards the head. Still wide in diameter, it pursues a meandering course closely applied to the body wall adjacent to the lateral columellar muscle (lcm). Its course so far agrees with the account of Brown (1934). As the anterior aorta turns forward, it gives a small vessel to the gut immediately posterior to the gizzard (rga). A similar vessel also approaches the gut from the left side of the body (lga); this probably originates from the base of the anterior aorta as in *Scaphander*. Continuing its lateral course, the anterior aorta passes between the origins of retractors IV and V and then through the double origin of the inner branch of the lateral columellar muscle (Figs. 6, 18, ilc, aa). Just before reaching the origin of this inner branch, a vessel leaves for the foot (Fig. 18, rpa). The anterior aorta then bends towards the mouth and divides to 2 parts. The dorsal one supplies the ganglia at the right side of the nerve ring and also gives a penial artery (pea) and one to the cephalic disc (rca). Around the nerve ring is a system of confluent sinuses enclosing the main commissures and connectives. These appear in dissection as a sheath around the nerves concerned (Figs. 14, 18, 19). Immediately anterior to the pedal commissure a large blood vessel, the pedal sinus artery (Figs. 14, 18, psa), runs in the thin sheath. Dorsal to the median columellar muscle (mcm) this vessel enlarges in diameter and gives

FIG. 18. *Philine.* Plan of the blood vessels of the anterior part of the animal with the gut removed. a, auricle; aa, anterior aorta; ba, buccal artery; cc, cerebral commissure; cd, cephalic disc; ct, ctenidium; ctv, ctenidial vessel; f, foot; gea; genital artery; hs, haemal sac; ilc, inner branch of lateral columellar muscle; lca, left cephalic artery; lcm, lateral columellar muscle; lga, left gizzard artery; loa, left oral artery; lpa, left pedal artery; m, mouth; mpa, median pedal artery; mv, mantle vessel; pao, posterior aorta; pc, pedal commissure; pca, pericardial cavity; pea, penial artery; psa, pedal sinus artery; rca, right cephalic artery; rga, right gizzard artery; roa, right oral artery; rpa, right pedal artery; spd, spermathecal duct; v, ventricle.

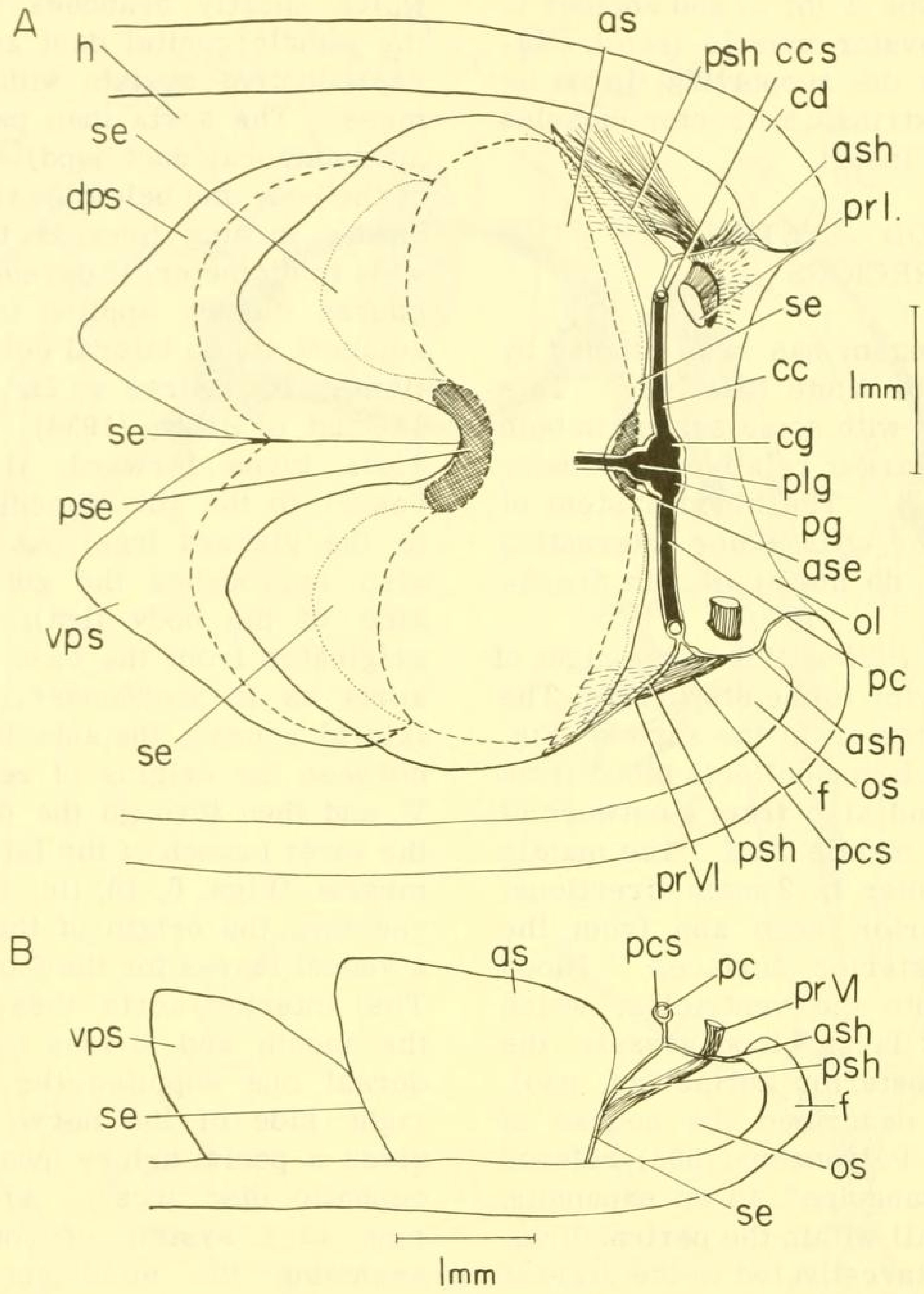

FIG. 19. *Philine.* a) Diagram of left anterior sagittal half with gut removed as in Fig. 14, to show relationship between blood sinuses and commissural sheaths. b) A longitudinal section through the ventral part shown in diagram a. The broken line indicates where sinus walls join the body wall. The finely dotted line shows the limits of septa between anterior and posterior sinuses and between anterior and oral sinuses. as, anterior sinus; ase, anterior sinus entrance; ash, anterior suspensory sheet; cc, cerebral commissure; ccs, cerebral commissure sinus; cd, cephalic disc; cg, cerebral ganglion; dps, dorsal posterior sinus; f, foot, h, haemocoel; ol, outer lip; os, oral sinus; pc, pedal commissure; pcs, pedal commissure sinus; pg, pedal ganglion; plg, pleural ganglion; pr I, VI, proboscis retractors I, VI; pse, posterior sinus entrance; psh, posterior suspensory sheet; se, septum; vps, ventral posterior sinus.

a fairly large buccal artery entering the buccal mass medially at its anterior limit (Figs. 4, 8, 14, 18, ba). A tiny vessel goes down to the foot, running between the muscle fibres associated with the parapedal commissure (Fig. 14, fcm, pc2; Fig. 18, mpa). The main vessel continues in the pedal sinus to the left side of the nerve ring. There blood leaves it to enter the nerve sinus system, to go to the foot in the left pedal artery (Fig. 18, lpa) and to the cephalic disc in another vessel (lca). Both branches of the anterior aorta continue forward as the oral arteries (roa, loa). In *Scaphander* these supply the lips and the anterior end of the oral tube. Vayssière (1880) mentioned the penial artery, 2 pedal and 2 cerebral arteries and the buccal supply. Brown (1934) described the anterior aorta as "connected with a system of sinuses".

The largest sinuses of the anterior region are very sizeable (Figs. 14, 19). They extend from the region of the nerve ring back nearly to the origins of proboscis retractors IV and V. In a sagittal section of the body with gut removed (Fig. 14) they may be seen as thin-walled bags joining the body wall at their edges. Four peaked bags are present on each side (Figs. 14, 19, as, dps, vps). The 2 anterior sacs (as) are confluent but are divided from the posterior ones by a dorsoventral septum (se) perforated only in the centre. The 2 posterior sacs represent dorsal and ventral sinuses separated by a horizontal septum. Blood can, however, pass from one to the other via the perforated septum between anterior and posterior sinuses. The limits of these sinuses have have been checked by the introduction of an air bubble. This bubble, on manipulation, proved them to be confluent by only a small gap , the posterior sinus entrance (Figs. 14, 19, pse), in the septum between anterior and posterior sinuses.

The large anterior sinus (Fig. 14, 19, as) is delimited anteriorly by another septum (Fig. 19a, 19b, se) formed by fusion of its wall with the posterior suspensory sheets (psh) of the cerebral commissure sinus (ccs) and the pedal commissure sinus (pcs). This septum is supported by fibres from the proboscis retractors I and VI (pr I, pr VI). The arrangement of anterior and posterior suspensory sheets (ash, psh) from the cerebral and pedal commissure sinuses (ccs, pcs) encloses a further cavity anterior to them, limited on the third side by the body wall and continuous around the extreme anterior end of the body, forming an oral sinus (os). The middle parts of proboscis retractors I and VI are free within the oral sinus but they are closely associated with the suspensory sheets (its walls) near their origins. Here fibres from both pairs of muscles run in the posterior suspensory sheet and each muscle passes through the anterior suspensory sheet to reach the oral tube. Some of the most anterior fibres of proboscis retractors I, originating from the outer lip rather than the cephalic disc, run within the anterior suspensory sheet. Because of the anterior suspensory sheet attaching to the outer lip from cerebral and pedal commissure sinuses blood escaping from the open anterior sinus entrance (ase) of the large lateral sinuses tends to pass to the haemocoel (h) median to the nerve ring.

There is extensive association between sinus walls and suspensory sheets with both muscles and nerves. Nerve c3 runs in the dorsal walls of the anterior sinus (Fig. 14, c3, as), its posterior branch following the posterior wall and its anterior branch the anterior wall. Similarly p4 (Fig. 14) runs with the posterior wall of the ventral posterior sinus (vps) and its anterior branch, pc2, runs in the anteroventral wall of the anterior sinus. The columellar muscle factors (fcm) associated with p4 and pc2 are even more close to the respective sinus walls. The suspensory sheets of the cerebral and pedal commissure sinuses also contain muscle fibres and fine nerves. Nerve c6 lies in the anterior suspensory sheet of the pedal commissure sinus and p 10 in its posterior suspensory sheet. Nerves cc2, pc3 and p8 run within the walls of the pedal commissure sinus itself during part of their course.

This account of the system of sinuses is necessarily incomplete due to a shortage of large specimens of *Philine*. The buccal artery was particularly difficult to fill successfully after it entered the buccal mass. Blood appeared to pass in front of the anterior transverse muscle and between the radular occlusor muscles, then on to either side of the radular sac. In *Scaphander*, which has a buccal mass similar in most respects, the course of

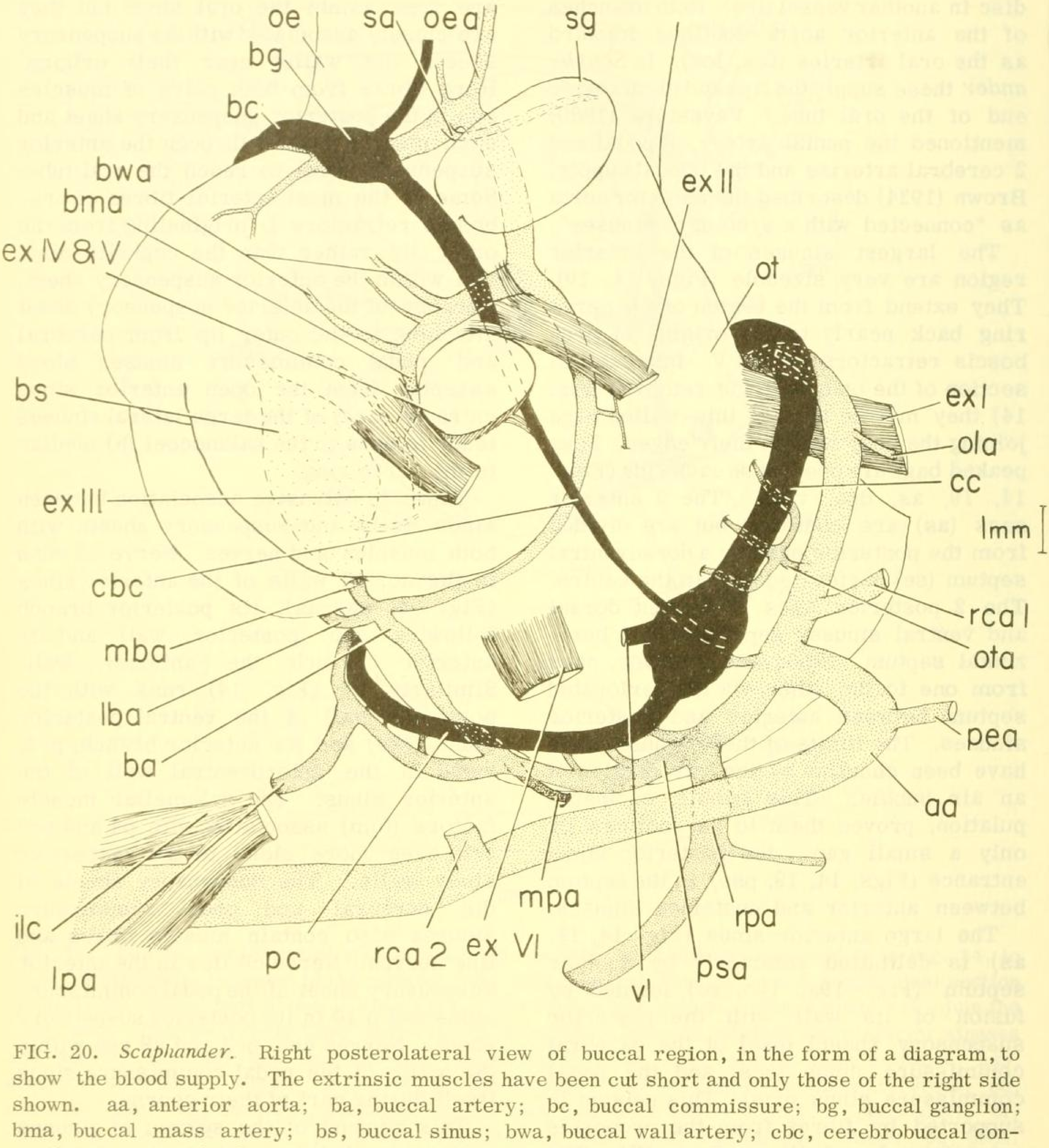

FIG. 20. *Scaphander.* Right posterolateral view of buccal region, in the form of a diagram, to show the blood supply. The extrinsic muscles have been cut short and only those of the right side shown. aa, anterior aorta; ba, buccal artery; bc, buccal commissure; bg, buccal ganglion; bma, buccal mass artery; bs, buccal sinus; bwa, buccal wall artery; cbc, cerebrobuccal connective; cc, cerebral commissure; ex I-VI, extrinsic muscles I-VI; ilc, inner branch of lateral columellar muscle; lba, lateral buccal artery; lpa, left pedal artery; mba, median buccal artery; mpa, median pedal artery; oe, oesophagus; oea, oesophageal artery; ola, outer lip artery; ot, oral tube; ota, oral tube artery; pc, pedal commissure; pea, penial artery; psa, pedal sinus artery; rca 1, 2, right cephalic arteries 1, 2; rpa, right pedal artery; sa, salivary artery; sg, salivary gland; vl, visceral loop.

blood was easier to trace (Fig. 20). In this animal the buccal artery (ba) also enters the buccal mass medially at its anterior ventral limit. A large outer branch, the lateral buccal artery (lba), departs to each side at the point of entry, and the median buccal artery (mba) continues to form a small sinus (bs) below the radula. Each outer branch passes up the lateral buccal wall and dorsally above the insertions of the buccal extrinsic muscles. It then divides to 2 parts. One continues dorsal to the salivary gland, to which it sends a small vessel (sa) and also supplies the buccal ganglion before reaching the oesophagus where it again branches (oea). The other part of the lateral buccal artery passes ventrally immediately posterior to the insertions of the extrinsic muscles. It supplies the intrinsic muscles of the buccal mass (bma) and the buccal wall (bwa). The large lateral buccal arteries of *Scaphander* are very obvious, but have not been seen in *Philine*. However, stain has sometimes reached the anterior part of the oesophagus and Vayssière (1880) mentioned 2 vessels going laterally around the buccal mass and up the oesophagus.

An important feature of the blood system in *Philine* (not in *Scaphander*) is the presence of haemal sacs (Figs. 14, 18, hs). These are thin-walled sacs which may be filled with blood, projecting from all sides into the posterior end of the main anterior body cavity, their long necks disappearing between the muscle fibres of the body wall. They can be easily filled with Nile blue by an injection made in the heart or anterior aorta. The stain does not then appear in the general haemocoel. The sacs are thus confluent with blood vessels and a few have been seen leaving the gizzard arteries and the anterior aorta (Fig. 18). The connections of the majority have not been traced. They are not filled by direct injection into the foot or cephalic disc.

In both foot and cephalic disc, there is a very extensive network of blood vessels (Fig. 18). The structure of the body wall consists of a thick layer of muscle fibres running in all directions. Amongst this spongework weave many interconnected vessels which can be filled by injecting respectively pedal or cephalic arteries. In *Scaphander* this network is not represented although the arteries branch several times. The area around the sensory patches can also be filled with blood via the pedal and cephalic arteries.

5. THE FUNCTIONING OF THE BUCCAL MASS INVESTIGATED BY STIMULATION

Three groups of movements have been observed in living *Philine* with the common effect of transporting food from the outside world to the oesophagus. The first concerns capture of prey. The walls of the buccal region of the gut are rolled inside out to a varying degree and the buccal mass is brought forward and through the mouth. The teeth open, seize prey (previously located by the sensory areas) by closing on it, and then drag it in. The second group of movements brings about release of prey to the oesophagus. The buccal mass, with teeth closed on the food, rises in the buccal cavity whilst the buccal region shortens, so that the dorsolateral thickenings of the oral tube meet. As they rise the rows of teeth open, releasing their burden to the oesophagus. The buccal mass then sinks, with teeth closing on the way. These 2 groups of movements alone constitute an efficient feeding process. The third group concerns searching for food with the proboscis fully protruded and often very active and mobile.

Stimulation experiments have been carried out with the aim of artificially reproducing some of the feeding movements and gaining evidence about the function of the muscles involved. Since protrusion of the proboscis is due to a complex interplay of muscular movements and changes in haemocoelic pressure, it has not been possible to produce it by electrical stimulation. Placing of the electrodes inevitably necessitates opening of the body cavity, which immediately removes all possibility of normal blood pressure changes, and pinning of the body wall means that muscular movements are no longer strictly normal. In spite of these difficulties it has been possible to simulate the rising and sinking movements involved in release of prey to the oesophagus in animals with proboscis in. In specimens with proboscis out a number of food-search and tooth movements have been evoked.

The stimulator used was built at the Royal Veterinary College, London, to the specification of Dr. R. H. Nisbet. Tapered silver electrodes, insulated at their tip with either Araldite (a commercial resin glue) or nail varnish, were set up in holders so that they could be moved in a horizontal or vertical direction. In later experiments the electrodes were modified: the silver wire emerging from the end of the glass holder was long and coiled in a spring; this gave it an ability to swing so that the electrode moved with the animal as it contracted.

The buccal ganglia are important as primary governors of the feeding process and as such have been the points of stimulation that yielded most information. It was attempted to analyse the general response resulting from stimulation of the buccal ganglia by stimulating individual muscles and nerves, but this method is subject to certain limitations: the size of the electrodes makes exact placing difficult; the nerves are often buried deeply amongst muscle fibres and the stimulus is therefore not precise; to reach certain of the intrinsic muscles it is necessary to cut others, and since muscles often work in functional groups the results may be unlike those seen in an intact animal. Particular difficulties in confining stimulation to one or a single pair of muscles are presented by the fact that one nerve trunk may branch to supply several muscles and unless the nerve is cut the stimulus may easily be transmitted to an area not in contact with the electrodes. Conclusions have been based on those results which seemed relatively normal.

Animals with proboscis in

Stimulation of the buccal ganglia was most easily done from the ventral side. The foot was cut open by 3 longitudinal cuts, 1 median, 2 just below the lateral tracts of the columellar muscle, from the posterior margin of the foot nearly to the mouth. A cut was made across the posterior edge of the foot joining the longitudinal cuts so that the foot could be turned forward in 2 triangular pieces and pinned out. This slightly stretched the buccal region by way of extrinsic muscles VI, the origins of which were now displaced and pinned anterior to the buccal region with the triangular pieces of foot. The stretching caused the angle between buccal mass and oesophagus to enlarge and thus made the buccal ganglia more accessible.

In a typical experiment a pair of electrodes was placed on each buccal ganglion giving stimuli of dial voltage 9 at a frequency of 1 stimulus every 2/3 sec. This produced a regular rising and sinking movement of the buccal mass within the surrounding superficial buccal musculature.

As the buccal mass rose, the whole buccal region became shorter and wider due to contraction of the extrinsic muscles I, II, III and VI. Extreme shortening of the oral tube caused its dorsolateral walls to meet and its floor to become very convex within the lumen. The postero-ventral bulge usually occupied by the buccal mass flattened, with the radular elevator muscle and radular sac almost disappearing under the buccal wall. The superficial buccal musculature contracted slightly but remained slack around the buccal mass. Since the lower half of the buccal mass moved upwards (by contraction of buccal tensors 2 and the radular elevator muscle) the buccal mass wall became stretched. This, combined with the contraction of the radular elevator muscle and outer oblique muscles, caused the radular membrane to be pulled laterally and flattened, thus opening the teeth. All the intrinsic muscles of the buccal mass wall contracted together.

In sinking the reverse happened. The buccal region elongated whilst its walls contracted, and were pulled in laterally due to contraction of the anterior transverse muscle. The superficial buccal musculature stretched around the sinking buccal mass and the posteroventral bulge became deep and prominent. The radula moved down and as a result the tip of the radular sac became pressed forward (helped by the pull of buccal tensors 3 which contracted) and could be seen protruding mid-ventrally. The teeth closed, partly due to lateral and posterior pressure from the buccal walls caused by the contracted anterior and posterior transverse muscles, but mainly due to contraction of the radular occlusor muscles. This was accompanied by relaxation of the radular elevator muscle, the outer oblique muscles and buccal tensors 2. Much of the radular sac and elevator muscle now projected below the posterior transverse muscle. Buccal tensors 4 contracted and helped to pull the radular sac down. The radular caecal fold was thus most prominent at this stage, and pressed down firmly over the radular sac. It was not widened by lateral stretch when the buccal tensors 4 contracted since their origins overlap, obviating the outward pull they would otherwise have given.

Direct stimulations of some of the muscles involved in the rising and sinking movements were carried out to see if the functions were what they would seem. The results may not be particularly reliable for the reasons already enumerated.

Intrinsic muscles contracting in the rising phase

The radular elevator muscle: A large number of experiments were carried out with 1 or 2 pairs of electrodes placed on the radular elevator muscle. With varying voltage and frequency it was possible to obtain several effects. These included a twitching of the muscle in unison with a stimulus of low voltage (9-15V) and frequency 1.5-3/sec. At 9V and 10-15/sec. a general contraction ensued and the radular sac moved up into the buccal cavity whilst the anterior end of the buccal mass wall moved slightly downwards. Stimulation of the radular elevator muscle also caused the teeth to open, sometimes rather jerkily, starting with the most anterior pair. In many animals the teeth remained closed at dial voltages up to 9V, but at 9V they opened and above this closed again. Ten per second seemed to be the frequency at which rapid twitches were absorbed into a single contraction.

Buccal tensors 2: It was sometimes possible to cause contraction of buccal tensors 2 by direct stimulation, but this was difficult due to the small size of the muscles and consequent difficulty in placing electrodes. When contraction occurred the tip of the radular sac moved up and towards the posterior transverse muscle.

Outer oblique muscles: Due to their size and situation, these muscles also proved difficult to stimulate directly when the buccal mass was not protruded. Results of stimuli applied when the proboscis was out proved that the outer oblique muscles are able to move the teeth closer together and towards the anterior transverse muscle. Stimulation of the corresponding muscles in *Scaphander* on one side only, with the buccal mass within the buccal cavity, caused the teeth of that side to open slightly.

Superficial buccal musculature: Rhythmic contractions can be induced by a stimulus of 9V at the rate of 1 every 2/3 sec. These are similar to those observed in the rising phase caused by stimulation of the buccal ganglia.

Oesophagus: Stimulation of the oesophageal nerve caused the buccal region to become dorsoventrally flattened as in the rising phase. After cutting the oesophagus from the buccal region and stimulating the cut edge above the buccal ganglia the buccal cavity and its oesophageal exit widened. Simultaneously the ventral floor of the oral tube moved up. If this is a genuine effect it would be useful when the radular teeth open in the rising phase, encouraging the released food to pass into the oesophagus.

Intrinsic muscles contracting in the sinking phase

The radular occlusor muscles: Stimulation of these has usually been with electrodes placed on the supporting tissue (st2) at the base of the muscles. Since the nerve supply is buried deeply here, it seems doubtful whether the stimulus would be very effective. In fact, in only one animal was contraction caused. On this occasion the whole buccal mass was pulled down promptly. The functional teeth were firmly closed with the radular membrane folded into a deep V-shape within the buccal mass wall. The radular occlusors are extremely large and are the most important muscles involved in closing and withdrawing the radula.

Buccal tensors 3 *and* 4: No reliable results were obtained in stimulating pair 3 because of the close association of these with the superficial buccal musculature and the radular occlusors. Pair 4 was not stimulated to give any decipherable result.

Posterior transverse muscle and buccal wall: These were stimulated through their nerve supply (b1, b2). This caused slight contraction and consequent squeezing of the buccal mass.

Anterior transverse muscle: It proved difficult to stimulate this muscle without transmitting the stimulus to extrinsic muscles II, III, IV and V. Contraction of the anterior transverse muscle with consequent approaching of the supporting tissues (st 1) was sometimes obtained. The radular occlusor muscles, anterior transverse muscle and buccal tensors 3 are all supplied by branches of a single nerve trunk - further circumstantial evidence for these all contracting together as a functional unit as they seem to do in the sinking phase.

Extrinsic muscles

Contraction of the proboscis retractors I, II, III and VI occurred during the rising phase. Their action was to protract the buccal mass whilst shortening the oral tube. They were stimulated in pairs directly. In contraction both their insertions and origins moved due to lack of haemocoelic pressure, which in an intact animal would prevent great retraction of the anterior region where these muscles originate.

Pairs I and VI: These on contraction pulled the oral tube forward, widening it at the same time; both thus tended to help in protracting the buccal mass. However, in very relaxed animals the origin of pair VI is sometimes posterior to its insertion when it will not cause protraction.

Pair II: These reacted readily to direct stimulus. When both were stimulated they shortened considerably and pulled the buccal mass forward. The posterior tract of fibres joining pair II below the oesophagus (see p 288-289) shortened and thus caused the posterior face of the buccal mass to become more vertical. As this occurred the teeth closed further, probably due to pressure from the surrounding walls. With stimuli repeated every 2/3 of a second, a nodding movement can be evoked in the buccal mass due to small regular contractions and relaxations of pair II.

Pair III: Contraction of these was easily induced by a stimulus of dial voltage 9 and frequency of 10/sec. It caused the buccal mass to move forward and down, advancing particularly at the basal end. When pair III contracts alone, it also causes some squeezing of the ventrolateral walls of the buccal cavity and consequent bulging dorsolaterally.

All contractions of proboscis retractors I, II, III and VI caused some protraction of the buccal mass. Their most effective contractions occurred when the large retractors IV and V, from the columellar muscle, were relaxed.

Pairs IV and V: Stimulation of these 2 at their bases caused the buccal mass to take up the sinking phase position. Similar effects could be obtained by stimulating the buccal nerve trunk before it divided near the entries of II, IV, V and III. More satisfactory stimulation of IV and V was given by placing the electrodes along their length not far from the side of the buccal mass. This caused contraction and consequent retraction of the buccal mass. Sometimes stimulation with electrodes on the cerebrobuccal connective caused contraction of IV and V. This is due to the fact that the nerve p9 which innervates them runs closely parallel to the connective and within the same sinus sheath.

When muscles IV and V are stimulated with the proboscis out, it is slightly retracted and, if the stimulus is on one side only, the buccal mass often twists towards the contracted muscles. These movements are caused by stimulus of any one of the proboscis retractors. All the proboscis retractors act as such whilst the proboscis is out, although their action may be so weak as to cause only slight movement in the direction in which they pull. The function of IV and V, however, is retraction of the buccal mass even when it is not protruded as part of the proboscis. The other proboscis retractors are in fact buccal mass protractors whilst the whole buccal region is within the main body cavity. If all 6 pairs of proboscis retractors contract together, their effects will thus oppose one another whilst the buccal mass is within the buccal cavity. When it is out, forming the ventral part of the proboscis, their effects will summate and retract it. In view of this it is obvious that contraction of the proboscis retractors must be in a definite sequence for protraction of the proboscis to occur. This sequence will be discussed later.

Other parts of the columellar muscle: Stimulation of these caused shortening of the body laterally or medially according to the position of the electrodes. Contraction of the lateral columellar muscle may close the lateral groove of the body. The role of the columellar muscle in protrusion of the proboscis is discussed below.

The regular rising and sinking movements of the buccal mass normally used in release of food from the radular teeth to the oesophagus may thus be experimentally induced. The muscles involved work together in groups. In rising, the radular elevator muscles, buccal tensors 2 and the outer oblique muscles cause the radula to be slightly projected from the buccal mass and opened by stretching the radular membrane laterally. Simultaneously muscles I and VI contract, shortening the oral tube, whilst II and III pull the buccal mass forward, tipping its free upper end slightly back towards the oesophagus. The dorsolateral walls of the oral tube meet due to its extremely shortened state, aided by contraction of its longitudinal muscles. Thus food is released by the opened teeth and, following the nearest available route, is able to go into the oesophagus. In the sinking phase, all these muscles relax whilst others come into action. The radular occlusors close the radular teeth and pull the radula down within the relaxed buccal mass walls, with the help of buccal tensors 3 and 4. The anterior and posterior transverse muscles contract and force the buccal mass down into the superficial buccal musculature. Proboscis retractors IV and V may contract and pull the buccal mass still further down and back. The accompanying squeezing of the buccal walls helps to send food into the oesophagus in a peristaltic manner.

Another feature occurring with regularity on appropriate stimulation is an indentation and relaxation of the region around the entry of the buccal artery. Indentation may be induced by stimulation of any one of pair III, buccal tensor 3, the superficial buccal musculature, the ventral tensor muscles of the oral tube, or the supporting tissues. All these have in common the fact that they are in contact with the transverse strand of Brown (1934) which has been described (p 289) as a strip of muscle fibres linking the two muscles III to which the superficial buccal musculature and ventral tensor muscles attach. The anterior transverse muscle, supporting tissues and buccal tensors 3 are in close contact with it. Indentation appears to be due to contraction of this transverse strand, possibly together with the ventral circular muscles of the oral tube. It would appear to have the function of closing the buccal artery at its buccal entry and allowing it to open when in-

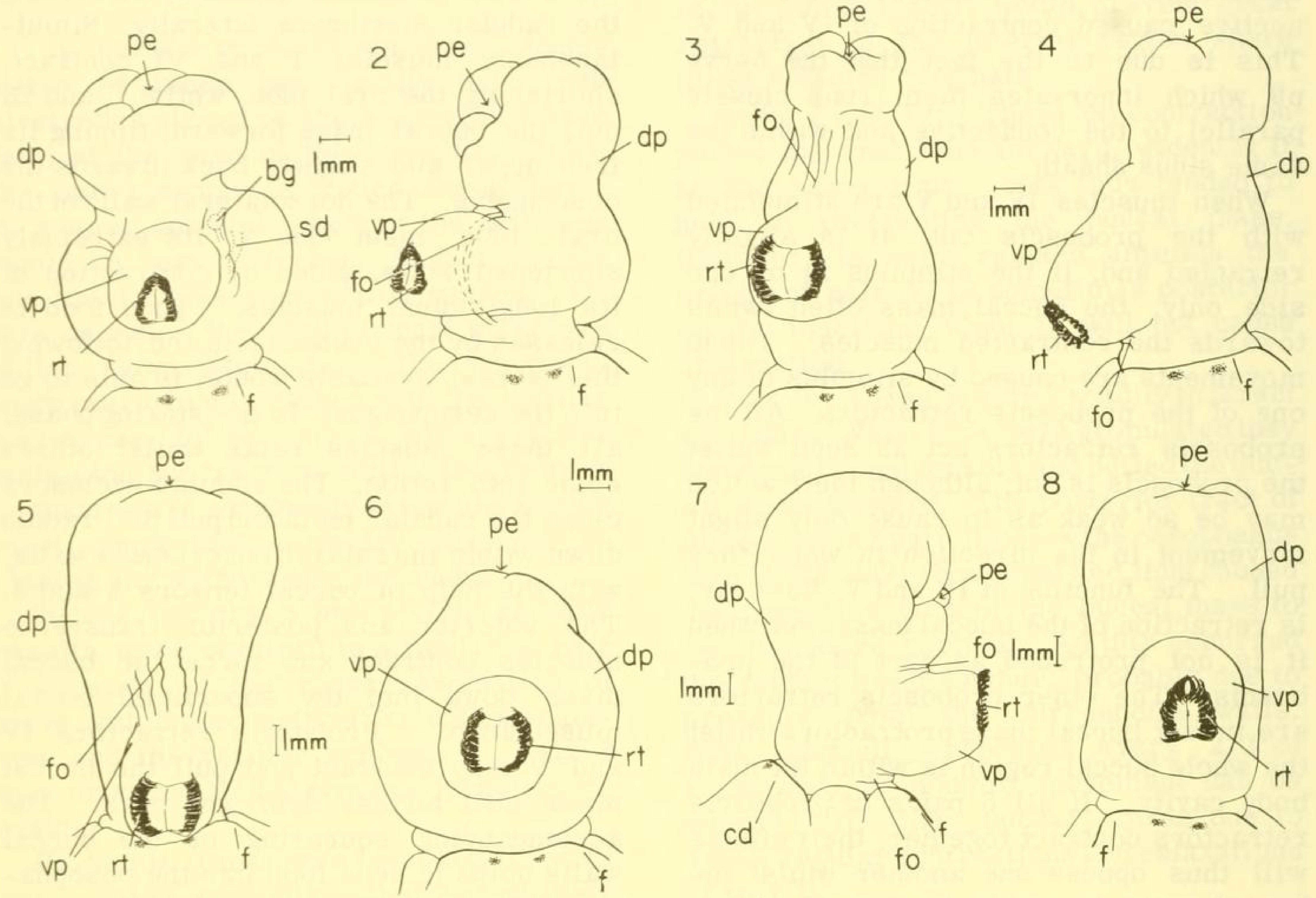

FIG. 21. *Philine*. Diagram to illustrate the changeable shape of the proboscis. bg, buccal ganglion; cd, cephalic disc; dp, dorsal part of proboscis; f, foot; fo, fold; pe, proboscis entrance; rt, radular tooth; sd, salivary duct; vp, ventral part of proboscis.

dentation ceases. This may have a circulatory function, allied to those described for *Haliotis* (Crofts, 1929) and *Monodonta* (Nisbet, 1953). Indentation may also help in opening the radular membrane by holding blood in the buccal sinus (Fig. 20, bs) and thus increasing turgidity. Its function in this respect cannot be fully elucidated since its timing has not been correlated with the sequence of the rising and sinking phases.

Animals with proboscis out

The everted proboscis is basically a dorsal fluid-filled bag and a ventral muscle-filled cylinder (Fig. 10). Between the 2 is the area covered by the pigmented buccal wall (Fig. 22a, bw) which undergoes great changes in its degree of contraction, particularly anteriorly and laterally. Leaving it laterally from within the proboscis are extrinsic muscles II, IV, V and III (Fig. 12). If the buccal wall contracts, the free parts of the salivary glands (sg) float towards the anterior end, in which position they are nearly always found on dissecting the proboscis. A more obvious feature of this contraction is that it causes the tip of the ventral cylinder to move anteriorly. Thus the angle between the base of the cylinder and the anterodorsal part of the proboscis becomes very small (Fig. 21, positions 2, 7). This effect is helped by contraction of buccal tensors 1. Great contraction has been observed in this area causing it to lie in transverse folds (Fig. 21, position 7). On relaxation the buccal wall usually bulges out (position 4) and the ventral cylinder moves to point posteriorly (vp), sometimes helped by contraction of the oral tube immediately posterior to it (fo). Lateral bending is induced by contraction and inpulling of the wall on one side of the cylinder base (position 2, vp, fo). These bending movements are helped by contraction of the proboscis retractors inserting in this area (see p 299) in different combinations. Bending in the cylinder itself was not very marked but was due to contraction of muscles running in its walls. It could be induced by stimuli applied to the buccal mass wall around the ventral part of the proboscis.

As may be seen in Fig. 21, the dorsal part of the proboscis is capable of considerable change in shape, pressure being provided by the intrinsic musculature of its walls; the changes are instigated and controlled by the nerve supply. They are sometimes accompanied by peristaltic movements of the inner part of the oesophagus, also innervated by the oesophageal nerve. The shape of the dorsal part of the proboscis varies from that of an elongated oval balloon (position 8, dp) to an hour-glass shape (positions 1, 2, dp). In the former case the diameter may be greater proximally (6, dp) or distally (5, dp). Some changes in shape may be due to inpulling of the oesophagus at its anterior entrance (pe). A change such as that from position 5 to 6 may be caused by stimulation of the tip of the proboscis. The proboscis entrance may be dorsal (Fig. 11, pe), anterior (Fig. 10; Fig. 21, positions 1, 3, 4, 5, 6, 8, pe), or ventral (Fig. 21, positions 2, 7, pe). Movement of the entrance from position 4 to 7 occurs on stimulation of the ventral part of the outer oesophageal wall. Proximal contraction due to intrinsic muscles often causes longitudinal wrinkling of the ventral wall and is accompanied by opening of the radular teeth to their widest (Fig. 21, positions 3, 5, dp, fo, rt); this can sometimes be produced by direct stimulation of the buccal wall. The rosette-like folds around the proboscis entrance may disappear due to a movement of fluid to this region from the squeezed area (f, pe, dp, fo). Carmine particles placed on the dorsal part of the proboscis will move into the entrance by ciliary action, but this is the only observed evidence of objects going in here.

When the radular membrane is flattened out as in the final stage of the rising movement previously described, the teeth open. They may remain wide open for long periods, but in general the most anterior rows are closed and the posterior ones partially open (Figs. 21 (1, 2, 4, 7, 8), 22a, rt). They can be fully closed, which is usually preparatory to complete or partial retraction of the buccal mass through the mouth. Sometimes they remain open until the buccal mass is almost withdrawn (Fig. 22b, rt). The width of the spaces between the rows of functional teeth may be altered. This has been caused experimentally by stimulation of the outer oblique muscles. The origin of these is posterior to their insertion in the proboscis, and when they contract the teeth move back and the posterior rows approximate more closely. Mechanical pressure on the base of the ventral part of the proboscis caused it to protrude and the teeth to open, whilst pressure on the posterior end of the radular membrane caused the teeth to close and be pulled well down into the cylinder whilst it moved back further into the proboscis.

6. PROTRUSION OF THE PROBOSCIS

By integration of the information already presented, it is possible to suggest the probable method of protrusion of the proboscis. Firstly, the functions of the muscles concerned have been deduced from their positions in animals at all stages between full withdrawal with strong contraction and full protrusion with a marked degree of relaxation. Secondly, observations on living animals have suggested the way in which the proboscis comes out. Thirdly, some experiments with mechanical pressure have afforded

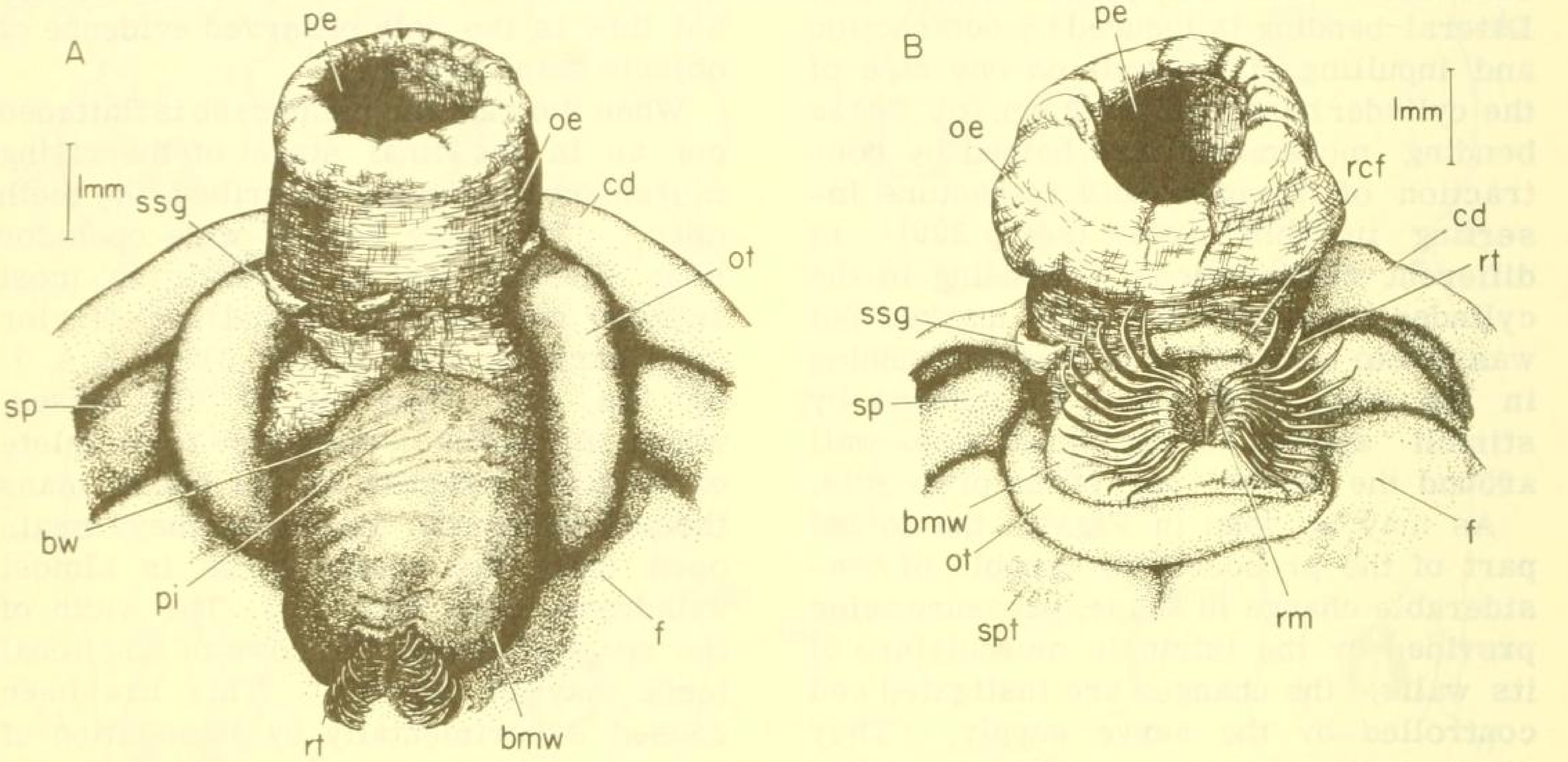

FIG. 22. *Philine.* Two anterior views of the proboscis partially collapsed prior to withdrawal, to illustrate the variable positions of the teeth, which may remain wide open until almost completely withdrawn. bmw, buccal mass wall; bw, buccal wall; cd, cephalic disc; f, foot; oe, oesophagus; ot, oral tube; pe, proboscis entrance; pi, pigment; rcf, radular caecal fold; rm, radular membrane; rt, radular tooth; sp, sensory palp; spt, sensory patch; ssg, secretion of salivary gland.

circumstantial evidence for the importance of blood pressure. Moreover, injections of the blood system have indicated that blood may be concentrated in certain areas and cause considerable local changes in pressure. Fourthly, the nerve supply of the anterior region has been found to be strongly concentrated around the sensory areas and the mouth, while the buccal mass and anterior gut walls are also well supplied with nerves. This indicates that the animal is capable of locating and identifying food easily and by virtue of very adequate musculature is able to perform diverse movements to capture it.

These sources provide a reasonable basis of support for the method of protrusion suggested. It is unfortunate that the major part of the information obtained from stimulation experiments concerned movements of the buccal region whilst within the body walls or after protrusion, and not during the process of moving from the one position to the other. The reasons for this have already been mentioned.

Before protrusion can occur it is necessary for the anterior region of the body to be suitably stretched. The process may thus be divided into 2 parts: the preparatory and the final phase. In the preparatory phase, this part of the body elongates, with the sensory palps exposed and the mouth open (Fig. 1, stage 1, sp, m). The dorsolateral thickenings of the oral tube are at first touching in the midline, closing the lumen, but then draw apart as the final phase begins. During this phase the inner lip (or rim of the oral tube) begins to bulge out (Fig. 1, stage 2, ot). The tip of the buccal mass appears and is pushed right out, followed by the anterior end of the oesophagus (stages 5-6). The latter then begins to expand above it, bringing about an appearance as in Fig. 1, stage 7. *Philine* may stay in the preparatory stage for long periods. During this time the proboscis may be pushed out by mechanical means, either by pressure applied externally just behind the buccal region (the more successful method) or (occasionally) by a quick injection of sea water into the main anterior body cavity. For either method to be successful the pressure rise must be speedy or the animal is apt to contract violently so that protrusion is no longer possible. This suggests that, provided the muscles are in suitable positions, the final stages of protrusion of the proboscis are brought about by blood pressure alone.

The first prerequisite for attaining the preparatory position is relaxation of the columellar muscle. This allows the foot to lengthen and the outer lips to be stretched forward, exposing the sensory palps. Fibres of the median and lateral columellar muscles enter the outer lips and overlap in a complete semicircle around the ventral part of the mouth (Fig. 16). These may represent the oral sphincter of Brown (1934) and Fretter (1939). Their relaxation enables the mouth to open widely. A further effect of columellar muscle relaxation is that its components proboscis retractors IV and V can lengthen so that they no longer pull the buccal mass firmly back within the anterior body cavity.

Extension of the body is partly due to flow of blood into the anterior region of the haemocoel. The anterior aorta may allow greater passage of blood when the columellar muscle has relaxed since it passes under part of the inner branch of the right lateral muscle (Fig. 6, aa, ilc) and is therefore probably constricted when the muscle is contracted. The factors of the columellar muscle (Figs. 14, 16, fcm) running in the walls of the large anterior sinuses may lengthen allowing them to expand fully. Another physiological valve affecting blood flow to the anterior body cavity occurs where the anterior aorta passes through the diaphragm or cephalic septum.

At this stage in the preparatory phase any pressure applied posteriorly to the buccal region of the gut could push it out as a proboscis, since the main anchors (retractors IV and V) no longer act as such, and the lips and regions adjacent to them are not pulled in to prevent passage of the proboscis.

Under natural conditions protrusion by increase in blood pressure is helped by contraction of 4 pairs of proboscis retractors, I, VI, II and III. The net effect of these draws the buccal region forward (Fig. 23). Since pairs I and VI are closely associated (p 313) with the anterodorsal and anteroventral walls of the anterior sinus (Fig. 19) they may tend to reduce its size, thus encouraging blood to flow out of the anterior entrance (ase). This blood would probably be unable to flow posteriorly since the widest part of the buccal region would fill the space in the body cavity median to the sinuses. Pressure by the buccal mass on their walls might even encourage blood to flow forward out of the sinuses helped by contraction of the inner muscular layer of the body wall, which reduces the diameter of the body cavity. Blood will thus tend to flow forward through the nerve ring, funnelled on by the anterior suspensory sheets from the cerebral and pedal commissures attached to the outer lip. It will thus cause the oral tube to bulge forward as in Fig. 1, stages 1 to 4 (ot) and Fig. 23 (stages 2-4).

The exact effects of proboscis retractors I, VI, II and III are as follows. Pairs I and VI act as dilators and protractors of the oral tube. After the mouth has opened in the preparatory phase of protrusion the inner lip stretches due to contraction of the circumoral muscles. Then, whilst the circular intrinsic muscles of the oral tube relax, pair I contracts more, separating the dorsolateral thicken-

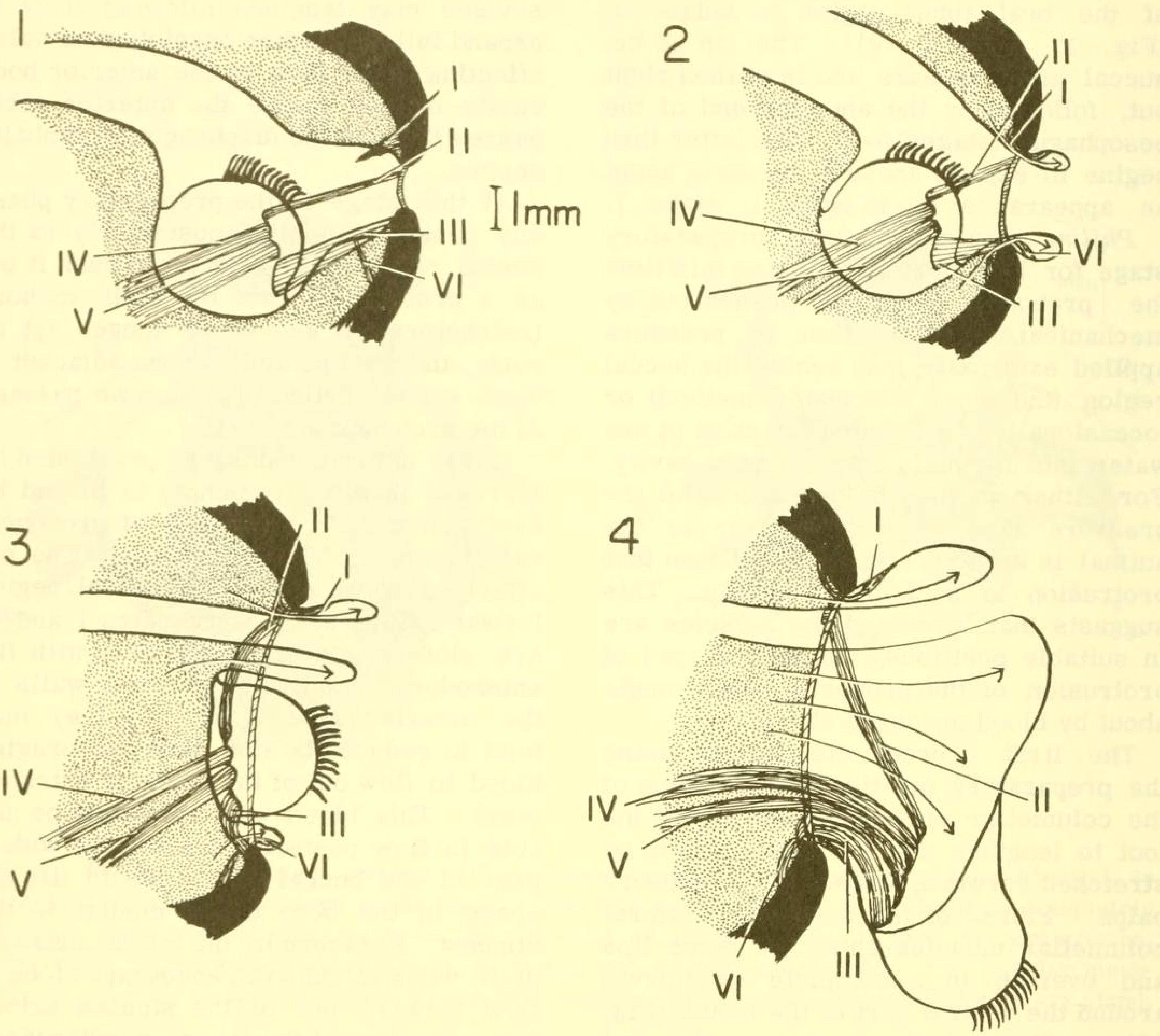

FIG. 23. *Philine.* Diagrammatic representation of 4 stages in the protrusion of the proboscis seen from the side by transparency. I-VI, proboscis retractors I-VI.

ings, and contraction of pair VI pulls down the floor of the oral tube. This results in enormous widening of the lumen. The oral tube simultaneously shortens due to contraction of its longitudinal intrinsic muscles and the ventral tensor muscles. Synchronously proboscis retractors II and III contract, pulling the buccal mass forward so that the radular teeth appear at the mouth (Fig. 23, stages 1-3). In these circumstances they act as protractors but cannot pull the buccal mass further than the region of their origins.

Anterior haemocoelic pressure builds up and besides flowing into the bulging oral tube, protruded inside out through the mouth, blood begins to press on the superficial buccal musculature surrounding the posterior part of the buccal mass. The buccal mass is pushed out through the mouth dragging after it the buccal wall and the oesophagus. The value of the 3 pairs of buccal tensors, 1, 2 and 4, in holding the walls of the buccal region firmly together and close to the buccal mass, is now of great account. Meanwhile, blood still enters the proboscis, forced in this direction by the approach of the large gizzard to the anterior part of the body (Fig. 11, gi). The dorsal wall of the buccal cavity and the oesophagus are also forced inside out to accommodate the fluid, and join the oral tube in forming the dorsal part of the proboscis (Figs. 10, 21, dp, Fig. 23, stages 3-4).

Thus during the final phase of protrusion the proboscis appears in 3 stages. Firstly, the oral tube widens and is brought forward, beginning to bulge inside out and to project through the mouth, surrounded by the greatly stretched outer lips (Fig. 23, stage 2). Secondly, the buccal mass is pulled forward and its tip appears encircled by the bulging oral tube (stage 3). The third and last stage involves the appearance of the oesophagus above the buccal mass, also surrounded by the oral tube. Eventually the oral tube and extreme anterior part of the oesophagus together form the blood-filled dorsal part of the proboscis, whilst the buccal mass is fully protruded as the ventral part (stage 4). The proboscis entrance is closed when the proboscis is turgid. All 3 stages depend on correlated changes in the degree of contraction of the intrinsic musculature of the gut walls, proboscis retractors and on the continued relaxation of the columellar muscle. The process of protrusion is helped and completed by increased blood pressure, itself due firstly to increase in the amount of blood in the anterolateral sinuses, secondly to reduction in their size by contraction of the extrinsic muscles I, VI, II and III, of the inner muscle layer of the body wall and by pressure from the forward-moving gut. As completion occurs all the proboscis retractors are relaxed, the buccal mass turns over the anterior transverse muscle and is held firmly by the ventral tensor muscles (see p 299).

As the buccal region passes out, the buccal ganglia and nerves go with it. This manoeuvre is facilitated since the cerebrobuccal connective and its accompanying nerve p9 are rooted in the adjacent anterior inner faces of their respective ganglia. No nerve roots obstruct the passage of the proboscis, whilst cerebral and pedal commissures are long and allow a maximum of space. The oesophageal nerves can follow the stretched contours of the oesophageal wall due to their initial meandering course.

The proboscis is withdrawn in an order not the reverse of the stages of protrusion. The buccal mass goes in first, followed by the oral tube and lastly the oesophagus. Withdrawal is preceded by a fall in blood pressure within the proboscis. The dorsal part collapses (Fig. 22, oe) and the buccal mass begins to be pulled in. The 6 pairs of proboscis retractors are responsible (directly or indirectly according to the position of their insertions) for drawing the buccal mass back through the mouth. The oral tube is pulled by the circumoral muscles and by contraction of its longitudinal intrinsic musculature, the ventral tensor muscles and proboscis retractors I and VI. The oesophagus does not appear to be easily withdrawn and this is eventually accomplished by the dragging effect of the retreating buccal mass and oral tube coupled with contraction of its own intrinsic musculature.

It is of interest to note that the haemal sacs of *Philine* lie between the 2 points of possible constriction of the anterior aorta. Their function is a matter for speculation. They probably do not help in the blood movements causing proboscis protrusion but may help to prevent re-protrusion as follows. Blood is likely to re-enter the anterior sinuses as well as the general haemocoel, when the proboscis is withdrawn. This could result in back-flow along the anterior aorta. When the animal is fully contracted - a state usually accompanying full retraction of the proboscis - both physiological valves controlling the anterior aorta are closed. This will prevent blood passing back into the heart or going forward again into the anterior sinuses. To accommodate large quantities of blood here the anterior aorta is large and moreover, haemal sacs are attached to it and will hold a further volume of fluid. This condition may continue until the buccal region is completely retracted and extreme contraction of the body ceases.

SECTION II
OTHER OPISTHOBRANCHS

The feeding apparatus has been briefly investigated in some other opisthobranchs, chosen for possible similarity to *Philine* in the method of obtaining food, and all burrowing forms of carnivorous habit. They include *Scaphander lignarius* (Linn.), *Acteon tornatilis* (Linn.), *Cylichna cylindracea* (Pennant), *Retusa obtusa* (Montagu), *R. umbilicata* (Montagu) and *R. truncatula* (Bruguière).

1. COLLECTION AND FOOD

Scaphander lignarius has been frequently dredged in small numbers with *Philine*, especially from deeper waters. Specimens were examined from the south and west coast of Great Britain: Plymouth, Millport and Anglesey. The food included bivalves (Plymouth, Millport), young sea urchins, Foraminifera, small tectibranchs (Plymouth) and *Pectinaria* (Anglesey). Debris in the crop and gizzard contained sand grains, diatoms and the hard parts of prey, such as radular teeth, pieces of shell. Previous authors described *Scaphander* as taking *Turritella* shells containing the gephyrean *Phascolosoma* (Vayssière, 1880; Guiart, 1901), gephyreans, molluscs and worms (Pruvot-Fol, 1954), whilst Fretter (1939) found *Turritella* in the gizzard, but did not indicate whether or not the shells contained *Phascolosoma*. This range of food is not unlike that described for *Philine*. *Scaphander* was not observed in the process of feeding, but is able to take relatively large prey. A specimen from Plymouth, 5 cm long, had taken a young bivalve (*Venus* sp.) which measured 1.1 cm length x 0.9 cm depth. Crop and gizzard measured 1.6 cm length x 1.8 cm depth, and the buccal region was 1 cm length x 0.6 cm depth. A similar specimen from Millport contained two *Corbula gibba*, each 1.2 x 1.0 cm, packed into the crop. Animals from Anglesey had taken enough *Pectinaria* to fill both crop and gizzard.

Spawning specimens of *Acteon tornatilis* were dug from Rhossili beach in the Gower peninsula, Bristol canal, South Wales. Many were dissected in order to determine their food, of which no previous account has been given. A number had taken *Owenia fusiformis*, but none was observed in the process of feeding.

Cylichna cylindracea and the 3 species of *Retusa* mentioned were dredged in the Øresund from Helsingør, Denmark. Preserved specimens of *Cylichna cylindracea* were obtained from Cullercoats, Northumberland. In one *Cylichna*, from the Øresund, a foraminiferan was found in the crop, but in other cases the food was not identifiable. Lemche (1956) suggested that *Cylichna* feeds on rhizopods. All dredge samples with large numbers of *Retusa* spp. came from stations in the Øresund where the bottom deposits were of fine sand at 14-20 m depth. Other specimens of *R. obtusa* were sent from Barry Island harbour, near Cardiff (Bristol Canal). These were collected from fine silty mud and their general diet has not been determined, although one had a foraminiferan in the crop. In the Øresund specimens the crop and gizzard were frequently filled with Foraminifera and sand grains, whilst in *R. obtusa* and *R. truncatula* rissoids had also been taken. In the crop of *R. truncatula*, the largest of the 3 species, an occasional small bivalve was also found. All survived well in a small aquarium with a good supply of Foraminifera. Bacescu and Caraion (1956) described 2 species of *Retusa* from the Black Sea as feeding almost exclusively on foraminiferans, whilst Jeffreys (1865) suggested that *R. alba* feeds on *Hydrobia ulvae*.

R. truncatula was observed feeding, during which process the mouth was widely open. This caused expansion of the lateral groove between the cephalic region and the foot (Fig. 24). The animal sucked in Foraminifera and sand grains from a small pile of debris in front of it. Feeding did not appear to be selective, but the numbers of foraminiferans present in the aquarium was very high so that

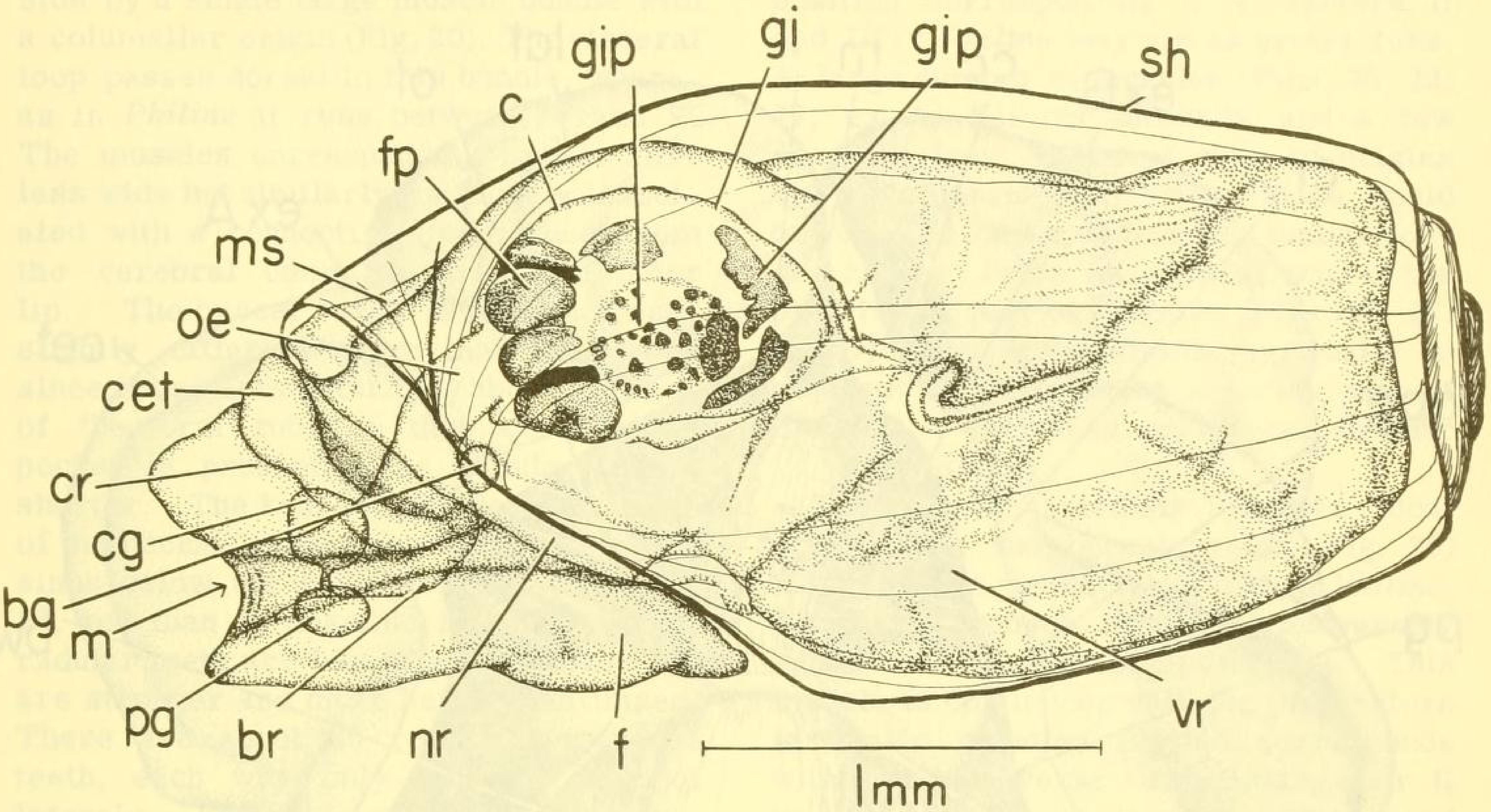

FIG. 24. *Retusa*. Left side view of whole animal seen by transparency through the shell. The mouth is stretched widely open to suck in food, whilst the entrance to the crop is constricted. The anterior part of the gut is shown by transparency. The crop is distended, containing part of a foraminiferan; the 3 gizzard plates can be seen, one in inner surface view, the other 2 (to the right of the diagram) are up-ended towards the left side. The cerebral, pedal and buccal ganglia of the left side are shown. bg, buccal ganglion; br, buccal region; c, crop; cet, cephalic tentacle; cg, cerebral ganglion; cr, cephalic region; f, foot; fp, food particle; gi, gizzard; gip, gizzard plate; m, mouth; ms, mantle skirt; nr, neck region; oe, oesophagus; pg, pedal ganglion; sh, shell; vr, visceral region.

any area presented an adequate proportion of food to sand grains. During feeding, the cilia on the cephalic region stopped moving; they normally beat in an antero-posterior direction sending small particles up over the dorsal side. Such ciliary currents have been observed in *Philine*, *Scaphander* and *Acteon*, and *Cylichna* (Lemche, 1956). Their action helps in burrowing, but would be disadvantageous to *Retusa* whilst feeding, since its food particles are small enough to be removed in a dorsal direction were the cephalic cilia in action.

2. FORM OF THE BUCCAL REGION AND OESOPHAGUS

In *Philine*, the anterior region of the gut comprises the buccal region leading to a much modified oesophagus, able to dilate into a large crop, behind which is an elaborate crushing gizzard with 3 large plates (Fig. 11, gip) bound together with muscle (gim). The whole lies within the spacious anterior part of the haemocoel. In *Scaphander*, *Cylichna* (Fig. 30) and *Retusa* (Fig. 31) this general pattern is repeated, whereas in *Acteon* (Fig. 25) the oesophagus is a simple tube conducting food to the stomach (Fretter & Graham, 1954). Another difference in *Acteon* is that the surrounding haemocoel is not spacious and the gut is closely attached to the body wall by small muscles.

In *Scaphander* the form of the buccal region and its associated musculature is essentially similar to that of *Philine*. The 5 pairs of extrinsic muscles correspond in position and relative length to proboscis retractors I-VI of *Philine*, with IV and V (p 289) represented on each

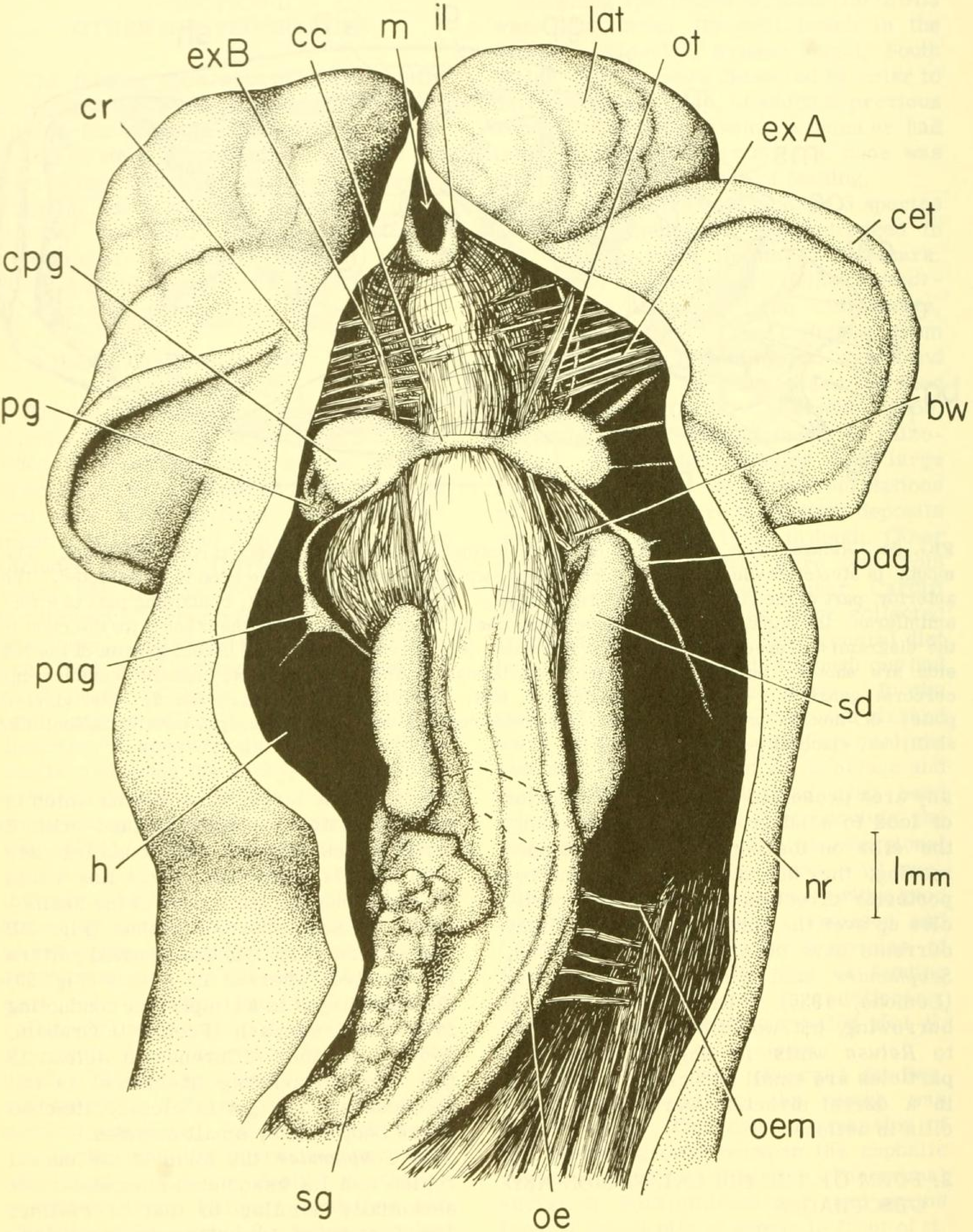
m
il
cc
lat
exB
ot
cr
exA
cet
cpg
pg
bw
pag
pag
sd
h
nr
lmm
oem
sg
oe

side by a single large muscle bundle with a columellar origin (Fig. 20). The visceral loop passes dorsal to this bundle, whereas in *Philine* it runs between IV and V. The muscles corresponding to pair I are less wide but similarly run closely associated with a connective tissue sheet from the cerebral commissure to the outer lip. The buccal mass is compact and slightly different from that of *Philine* since it projects anteriorly above the floor of the oral tube so that a sublingual pocket is present; the radular sac is shorter. The keel-shaped anterior bulge of the buccal mass accommodates a larger sinus below the radular membrane (Fig. 20, bs) than is possible in *Philine*. The radular teeth are like those of *Philine* but are stronger and more heavily chitinised. There are about 25 rows of functional teeth, each with only a single pair of laterals. Each side of the radular membrane seems to be capable of great movement along the longitudinal axis of the buccal mass; thus, for instance, the left side may be placed in advance of the right, so that several teeth become anterior to their right counterparts. Opening into the buccal cavity above the buccal mass are the short, cylindrical salivary glands (Fig. 20, sg); they are otherwise unattached to the gut (a condition described by Vayssière (1880) as confined to *Philine* and *Scaphander*). The large gizzard of *Scaphander* (p 326) has already been adequately described by Vayssière (1880), Lacaze-Duthiers (1898), Guiart (1901) and Fretter (1939).

In *Acteon* the buccal region is tightly enclosed in the haemocoel, and its musculature differs from that of *Philine* (Figs. 25, 26). The extrinsic muscles include none which could retract it, but 2 small pairs (Fig. 26, ex B, ex C) in a position corresponding to retractors II and III of *Philine* may act as protractors. A large number of muscles (Figs. 25, 26, 27, ex A) fan out laterally and a few dorsally from the oral tube to origins on the adjacent body wall: these would be capable of expanding the lumen considerably. From the ventral wall of the oral tube a pair of muscles (Figs. 26, 27, ex D) runs down almost vertically to adjacent origins in the anterior part of the foot; they may correspond to pair VI of *Philine*.

The outer intrinsic muscle coat surrounding the buccal region (Fig. 26) is relatively weaker than that in *Philine*. There is a muscle running transversely below the buccal commissure. This muscle is continuous with the protractors (extrinsic muscles B) and corresponds with the transverse band linking pair II in *Philine*. A conspicuous median band of longitudinal fibres runs from below the transverse muscle to join the ventral longitudinal fibres of the oral tube. A similar tract in *Cylichna* is shown in Fig. 28. The oral tube is relatively long and wide, and its intrinsic musculature recalls that of *Philine*. Lying below the above-mentioned longitudinal fibres (= ventral tensors of *Philine*) a large number of well marked muscles run transversely, corresponding to the ventral circular muscles of *Philine*. They continue up below the weak lateral longitudinal muscles, disappearing below the dorsal longitudinal ones. Posterior to the oral tube the buccal walls are laterally thickened (lt). A second protractor (extrinsic muscle C) leaves from the anterior limit of the thickening.

In the sagittal section (Fig. 27) the jaws (j) are shown. These lie approximately level with the extrinsic muscles

FIG. 25. *Acteon*. Anterior region opened by a mid-dorsal longitudinal cut to show the buccal region of the gut. The visceral loop on the right side, which normally crosses above the gut, has been displaced. bw, buccal wall; cc, cerebral commissure; cet, cephalic tentacle; cpg, cerebropleural ganglion; cr, cephalic region; ex A, B, extrinsic muscles A,B; h, haemocoel; il, inner lip; lat, labial tentacle; m, mouth; nr, neck region; oe, oesophagus; oem, oesophageal muscles; ot, oral tube; pag, pallial ganglion; pg, pedal ganglion; sd, salivary duct; sg, salivary gland.

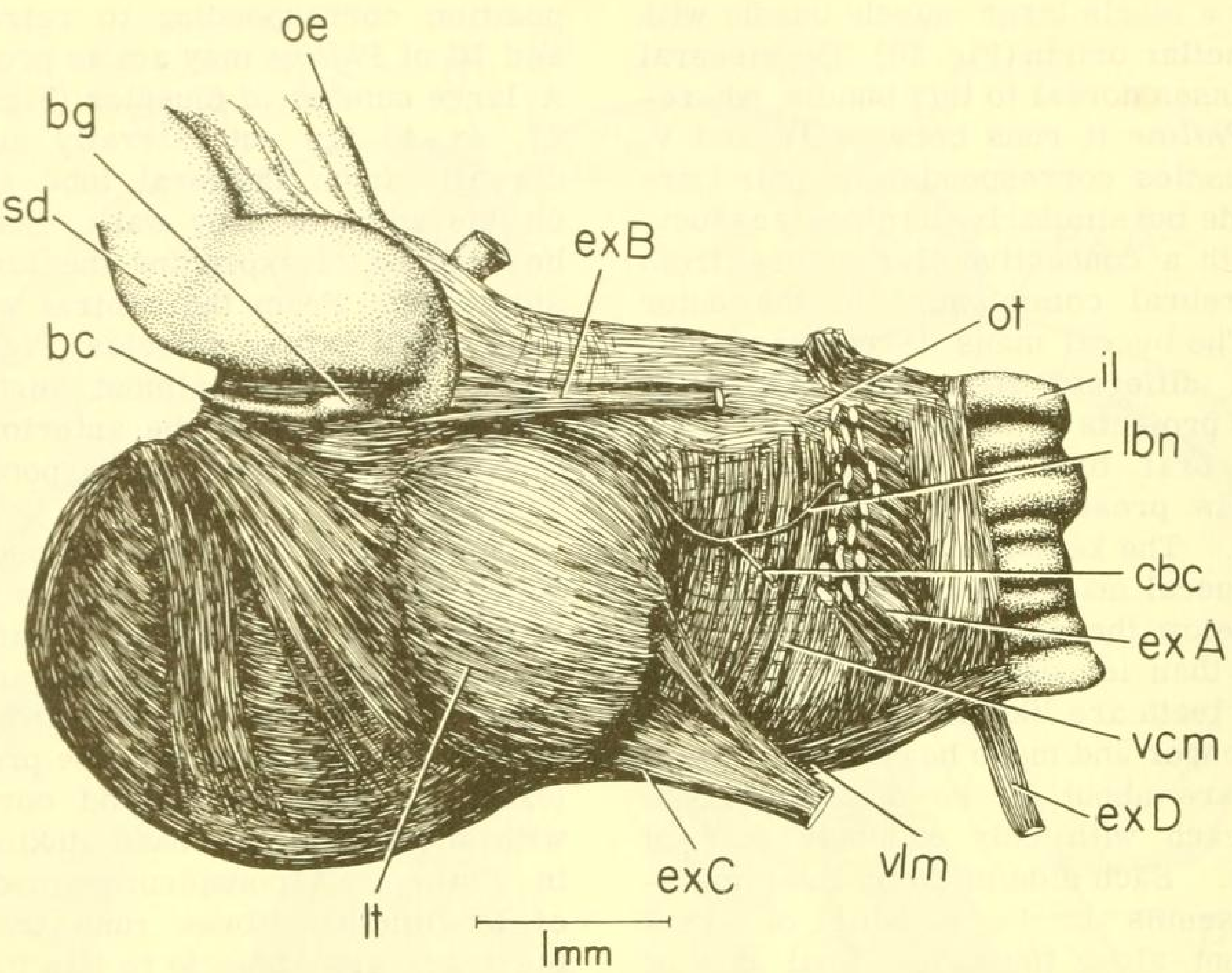

FIG. 26. *Acteon.* Lateral view of the buccal region removed from the body cavity. The extrinsic muscles are cut short. bc, buccal commissure; bg, buccal ganglion; cbc, cerebrobuccal connective; ex A-D, extrinsic muscles A-D; il, inner lip; lbn, lateral buccal nerve; lt, lateral thickening; oe, oesophagus; ot, oral tube; sd, salivary duct; vcm, ventral circular muscle; vlm, ventral longitudinal muscle.

A. Their structure has been described by Gabe and Prenant (1953) and by Fretter and Graham (1954) who have also discussed the radula. The buccal mass has a form quite unlike the firm cylindrical structure of *Philine* and *Scaphander*. In *Acteon* the radular membrane (rm) is similarly longitudinally grooved in the midline, but is much more extensive, spreading on each side up and over the edge of the flattened lateral cushion representing the remainder of the buccal mass. Each cushion is semicircular in sagittal section and is attached to the buccal wall (bw) ventrally and laterally. Posteriorly it bears 2 vertical transverse grooves into which the radular membrane fits. They may represent the radular sac, but there is no caecum containing the developing teeth as in other opisthobranchs. The inner surfaces of the radular membrane on the lateral cushions are closely apposed and covered with many rows of minute teeth (rt). In each row the teeth are similar and very numerous. The lateral cushions are composed of connective tissue with deposits of calcium salts and glycogen (Gabe and Prenant, 1953). The salivary ducts (esd) open dorsal to the cushions in a posterolateral position. They and the salivary glands (sd, sg) are long and bulky, lying folded adjacent to the oesophagus (oe), to which they are superficially attached. Many fine muscle strands attach the oesophagus to the body wall (Fig. 25, oem).

The buccal region of *Cylichna* has been extensively investigated by Lemche (1956) and his account has been checked in several respects, although the full details of the intrinsic musculature have

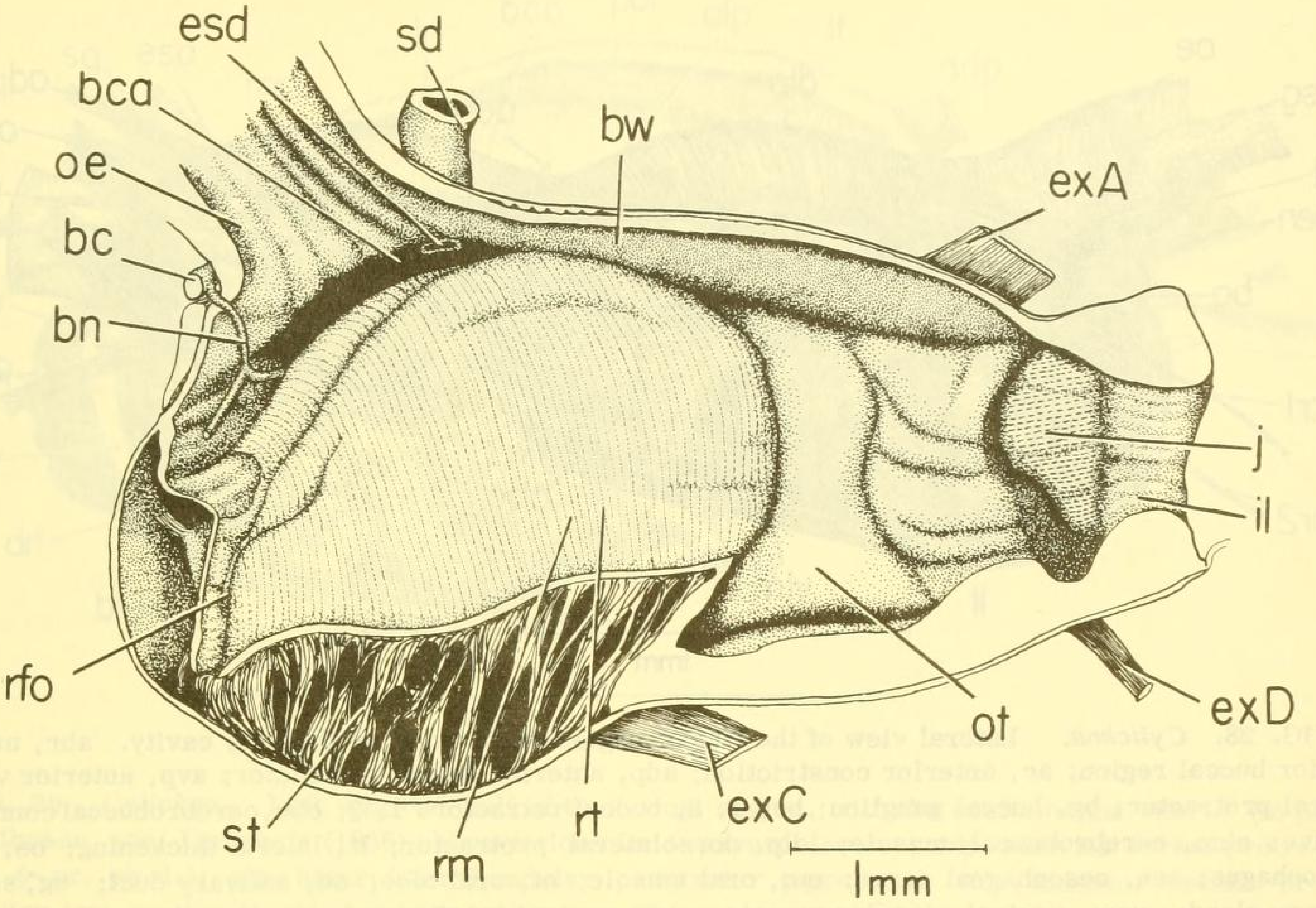

FIG. 27. *Acteon.* Left sagittal half of the buccal region. bc, buccal commissure; bca, buccal cavity; bn, buccal nerve; bw, buccal wall; esd, entry of salivary duct; ex A,C,D, extrinsic muscles A, C, D; il, inner lip; j, jaw; oe, oesophagus; ot, oral tube; rfo, radular fold; rm, radular membrane; rt, radular tooth; sd, salivary duct; st, supporting tissue.

not been studied. This region is the most elongated amongst the opisthobranchs surveyed here. It is divided into 2 parts visibly separable by the differing amount of intrinsic musculature thickening their walls (Figs. 28, 30). Between the 2 is the anterior constriction (ac) described by Lemche (1956). Posterior to this constriction the walls are muscular and are comparable with those of the buccal region of *Philine* (Fig. 5) or *Acteon* (Fig. 26). Anterior to the constriction the walls of the oral tube are much folded longitudinally and are glandular. It is this part which gives added length to the buccal region. Around the anterior constriction lies the nerve ring (Fig. 30).

Several pairs of extrinsic muscles attach the buccal part of the gut to the body wall. Two small pairs (Figs. 28, 30, om), undescribed by Lemche (1956), leave its extreme anterior end and run to the outer lip; these are comparable with the circumoral muscles of *Philine*. Two larger pairs insert on the muscular wall of the gut just posterior to the anterior constriction. One pair is laterodorsal (Figs. 28, 30, adp) with a fairly wide insertion. The muscles are long, flattened and run forward under the cerebral commissure (Fig. 30, cc) afterwards turning dorsally and outwards to origins in the cephalic region of the body wall. The second pair inserts on the ventral longitudinal intrinsic muscles (Fig. 28, avp, vlm) and runs forward through the nerve ring to pedal origins. These 2 pairs may protract the muscular part of the buccal region and might represent either pairs I and VI (from the position of the insertions) or pairs II and III (functionally) of *Philine*. They

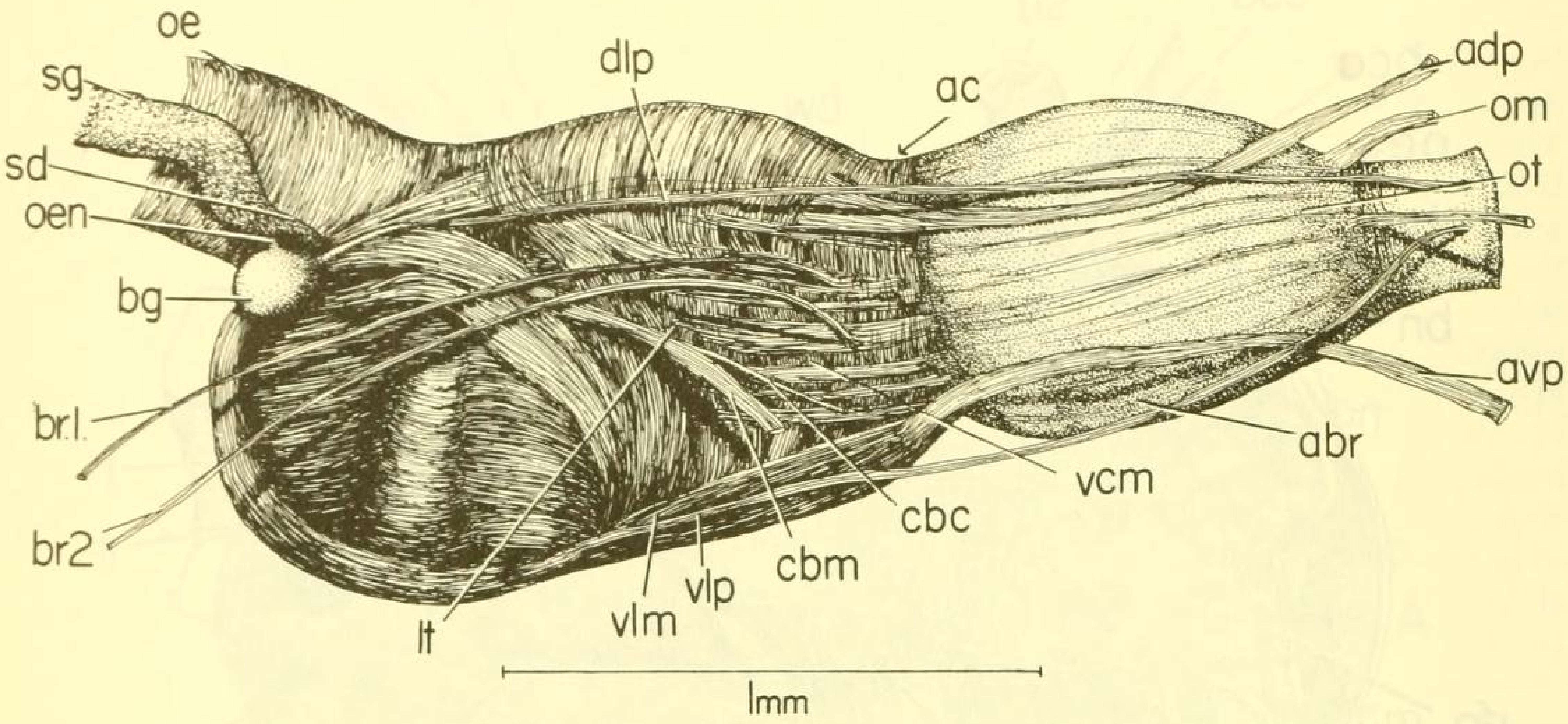

FIG. 28. *Cylichna*. Lateral view of the buccal region removed from the body cavity. abr, anterior buccal region; ac, anterior constriction; adp, anterior dorsal protractor; avp, anterior ventral protractor; bg, buccal ganglion; br, 1, 2, buccal retractors 1, 2; cbc, cerebrobuccal connective; cbm, cerebrobuccal muscle; dlp, dorsolateral protractor; lt, lateral thickening; oe, oesophagus; oen, oesophageal nerve; om, oral muscle; ot, oral tube; sd, salivary duct; sg, salivary gland; vcm, ventral circular muscle; vlm, ventral longitudinal muscle; vlp, ventrolateral protractor.

are called dorsal and ventral protractors of the pharynx by Lemche. As he described, their insertions are level with the jaws. A further 2 pairs of dorsal and ventral protractor muscles are present: Lemche's protractor pharyngis dorsolateralis and protractor pharyngis ventrolateralis. Their insertions correspond to those of pairs II and III in *Philine*, but they originate in the extreme anterior end of the oral tube (Fig. 28, dlp, vlp, ot), not from the outer lip. Each pair is elongated and passes through the nerve ring outside the protractors mentioned above (Fig. 30). These muscles could protract the buccal mass by shortening the buccal region. Lemche mentioned the possible presence of a retractor muscle leaving from near the place where the cerebrobuccal connective leaves the buccal wall. His statement may refer to one of two undescribed pairs of extremely minute retractor muscles (Figs. 28, 30, br 1, br 2) which leave from a point approximately between the insertions of the more anterior dorsal and ventral protractors (level with the jaws). Each pair is very long and runs back to the foot (Fig. 30) probably with a columellar origin. These retractors may correspond to pairs IV and V of *Philine*. However, they are so small that they would hardly be adequate to pull the buccal region back within the body cavity. A further pair of extrinsic buccal muscles (cbm) is that leaving the lateral columellar muscle on each side to run to the buccal wall adjacent to the cerebrobuccal connective (cbc), which, in fact, runs within the muscle for at least part of its length. This muscle was represented by a few fibres only from the base of retractor V in *Philine* (p 289), but is well marked in *Cylichna*. Lemche described it as the musculus cerebrobuccalis.

The positions of the muscle fibres in the outer muscle coat of the posterior half of the buccal region (Fig. 28) have not been particularly studied in relation

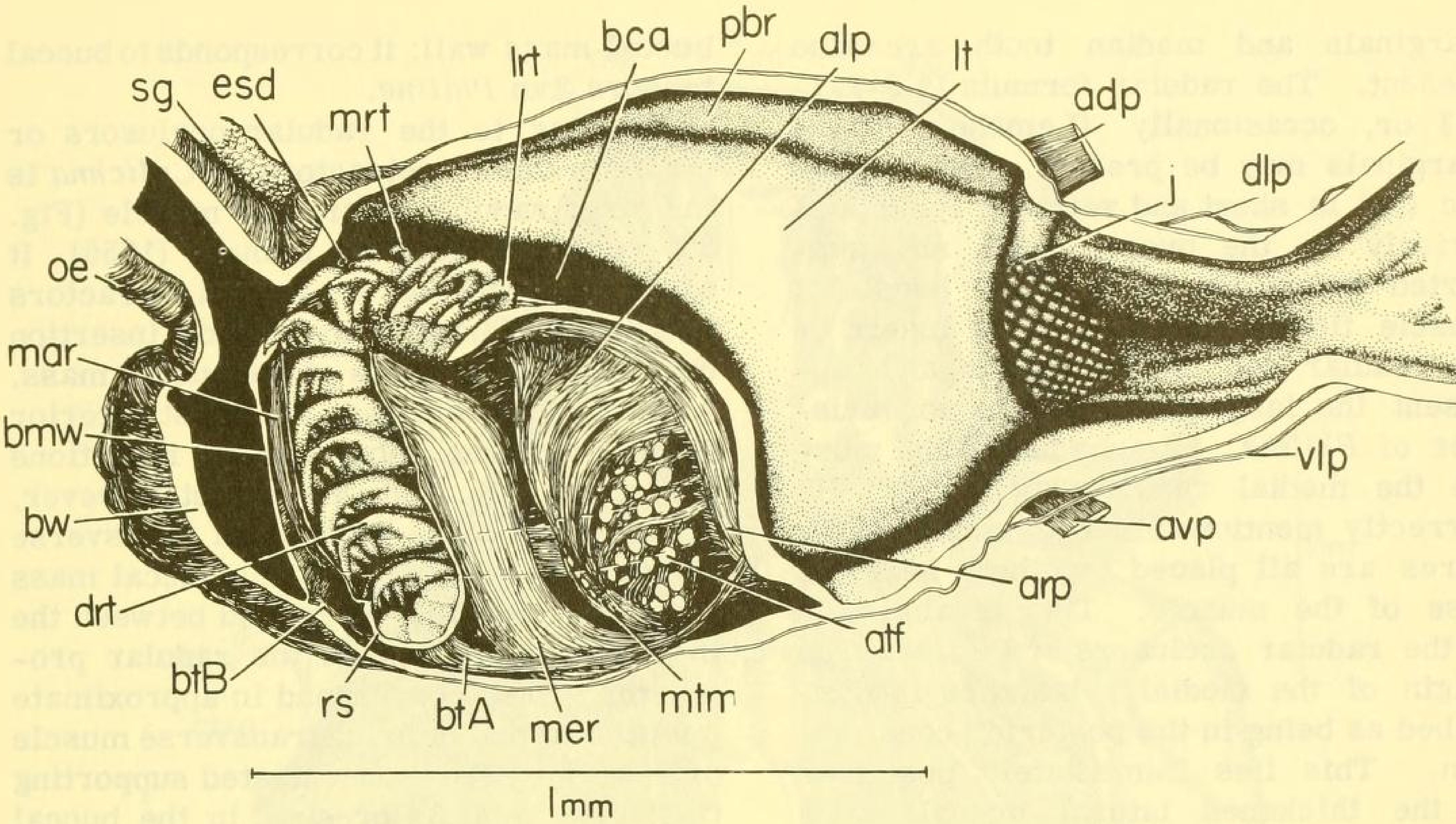

FIG. 29. *Cylichna*. Left sagittal half of the buccal region, with the oral tube cut short. (In parentheses are Lemche's (1956) abbreviations for the musculature.) adp, anterior dorsal protractor (= pr. ph. d.); alp, anterolateral radular protractor (=pro. ra.); arp, anterior radular protractor (=m. ro. d-v.); atf, anterior transverse fibres; avp, anterior ventral protractor (=pr. ph. v.); bca, buccal cavity; bmw, buccal mass wall; bt A, B, buccal tensors A (=m. pp. lo.), B; bw, buccal wall; dlp, dorsolateral protractor (=pr. ph. d-l.); drt, developing radular tooth; esd, entry of salivary duct; j, jaw; lrt, lateral radular tooth; lt, lateral thickening; mar, marginal retractor (=re. r. ma.); mer, median retractor (=re. r. me.); mrt, marginal radular tooth; mtm, median transverse muscle (=m. ro. tr.); oe, oesophagus; pbr, posterior part of buccal region; rs, radular sac; sg, salivary gland; vlp, ventrolateral protractor (=pr. ph. v-l.).

to Lemche's account (1956), but of those mentioned by him, the following are certainly present: the longitudinal ventral muscle (vlm, corresponding to the ventral tensors of *Philine*), the circular muscles concentrated around the anterior constriction, the U-shaped strong dorsoventral muscles (vcm, as in *Philine*), the transverse dorsal muscles (which are very obvious on dissection), the longitudinal dorsal muscles (consisting of very few fibres indeed). The 'buccal muscle' of Lemche is well marked and corresponds to the posterior band linking retractor pair II in *Philine*. The relationship in *Cylichna* of the buccal muscle to the dorsolateral protractors is also very similar. Very obvious were the radial and 'internal dorsoventral' muscles, which cause thickening of the lateral buccal walls immediately anterior to the buccal mass. These are also represented in *Philine* but are more scattered and irregular, with much spongy connective tissue between them. Some strongly marked intrinsic muscle tracts shown in Fig. 28 do not seem to agree entirely with Lemche's account but probably represent his musculus masticatorius and m. pharyngis posterior.

The form of the buccal mass and its more immediately obvious intrinsic muscles are shown in sagittal section (Fig. 29). Its shape is similar to that of *Scaphander* in that it bulges forward anterior to the rows of functional radular teeth. Each row in *Cylichna* consists of several teeth (rt). The laterals are strong and hook-shaped with wide bases, as in *Philine* and *Scaphander* but marginals and median tooth are also present. The radular formula is 3-1-1-1-3 or, occasionally (Lemche, 1956), 4 marginals may be present. The radular sac (rs) is short and vertical, lying posteriorly in the buccal mass and supported anteriorly by a large bundle of muscle fibres (mer). These insert on the radular sac and membrane and represent the large radular occlusor muscles of *Philine*. Lemche called the muscle the medial radular retractor. He correctly mentioned that the nuclei of the fibres are all placed together, near the base of the muscle. This is also true of the radular occlusors of *Philine*. The origin of the medial retractors is described as being in the posterior constriction. This lies immediately posterior to the thickened lateral buccal walls mentioned above, is by no means as obvious as the anterior constriction and hardly deserves emphasis.

Two other muscles are described by Lemche (1956) as inserting on the radular sac. Of these, one is the marginal radular retractor originating outside and above the medial retractors and inserting on the posterior surface of the radular sac (Fig. 29, mar). It probably also inserts on the part of the radular membrane bearing functional teeth. It is difficult to compare this muscle with any found in *Philine*. The other muscle described by Lemche is comparable to buccal tensors 3 of *Philine* (bt A). Another small muscle (bt B), not mentioned by him, inserts in the tip of the radular sac and passes back to the posterior junction between buccal wall and buccal mass wall; it corresponds to buccal tensors 2 in *Philine*.

Anterior to the radular occlusors or medial radular retractors of *Cylichna* is the large radular protractor muscle (Fig. 29, rpr) described by Lemche (1956). It originates between the medial retractors and bends forward to a wide insertion on the anterior walls of the buccal mass. As Lemche mentioned, the most anterior fibres with the most ventral insertions are strongly curved. He did not, however, discuss the large number of transverse fibres (atf) which cross the buccal mass from side to side below and between the most ventral fibres of the radular protractor. They correspond in approximate position to the anterior transverse muscle of *Philine*. The concentrated supporting tissues 1 and 2, present in the buccal mass of *Philine* are not represented in *Cylichna*. The only transverse fibres described by Lemche are those close to the most posterior part of the radular protractor which he calls m. rotellae transversus. The fibres appear in Fig. 29 (mtm). The remaining large dorsoventral muscle (arp) described by Lemche corresponds in general position and function to the outer oblique muscles of *Philine*. The circular intrinsic muscles of the buccal mass wall are present as in *Philine*.

The large jaws (j) are another feature of the buccal region obvious in a sagittal section (Fig. 29). Their anterior edges are slightly serrated while their posterior edges curve out into the buccal wall. The inner surfaces are covered with even rows of pointed tubercles, each with a square

FIG. 30. *Cylichna*. Anterior region opened by a mid-dorsal longitudinal cut. The crop and gizzard have been cut open with a laterodorsal longitudinal incision on the left side. The cerebral commissure has been cut and the ganglia of the left side pulled outwards by means of the left cut end of this commisure. aa, anterior aorta; abr, anterior part of buccal region; adp, anterior dorsal protractor; avp, anterior ventral protractor; br, 1,2, buccal retractors 1,2; c, crop; cbc, cerebrobuccal connective; cbm, cerebrobuccal muscle; cc, cerebral commissure; cet, cephalic tentacle; cg, cerebral ganglion; cr, cephalic region; dlp, dorsolateral protractor; f, foot; gim, gizzard muscle; gip, gizzard plate; glr, glandular ridge; h, haemocoel; ilc, inner branch of lateral columellar muscle; lcm, lateral columellar muscle; m, mouth; nr, neck region; oe, oesophagus; om, oral muscle; ot, oral tube; pbr, posterior part of buccal region; pg, pedal ganglion; plg, pleural ganglion; sg, salivary gland; sh, shell; soe, supra-oesophageal ganglion; stc, statocyst; trm, transverse muscle; vl, visceral loop; vlp, ventrolateral protractor.

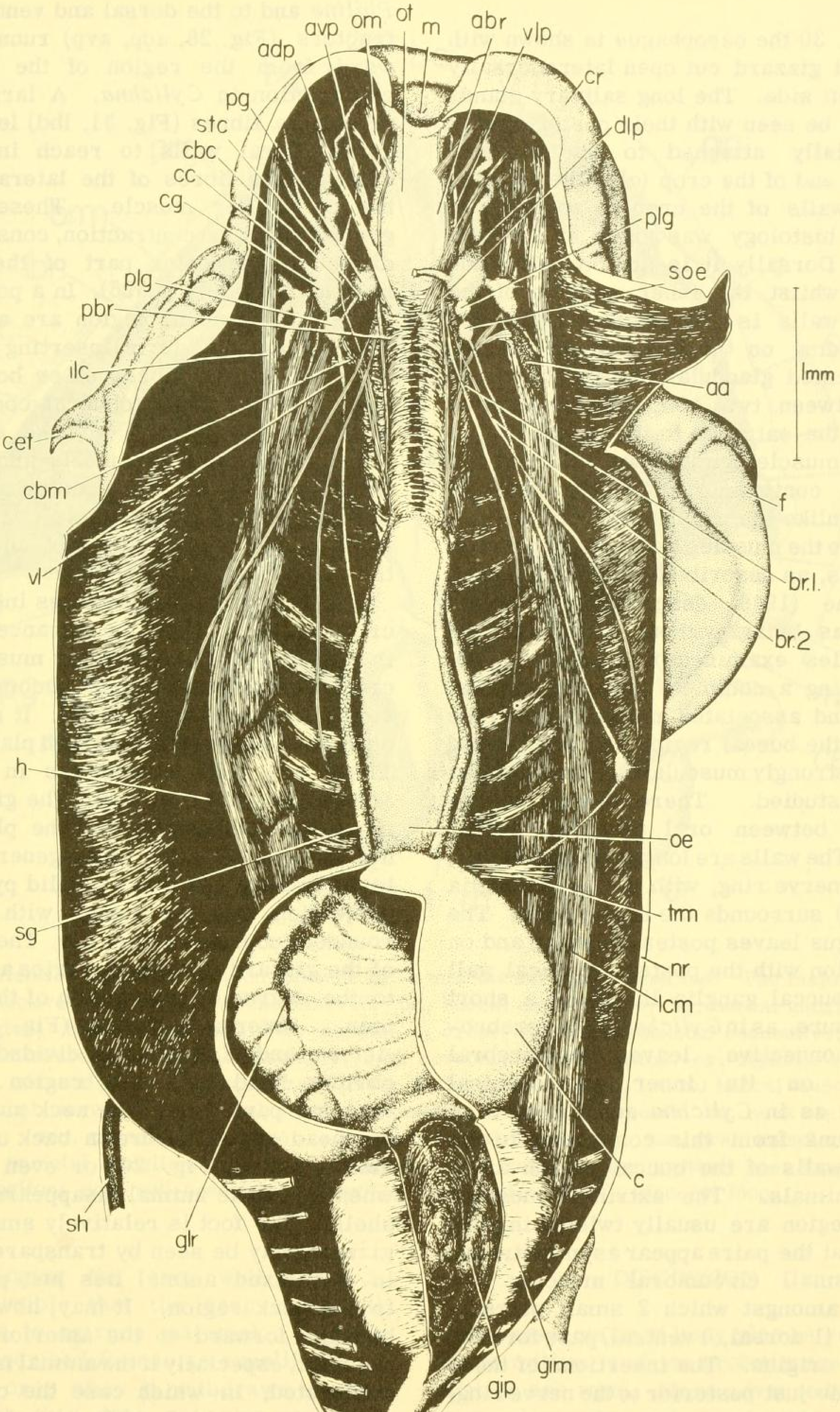
adp
avp
om
ot
m
abr
vlp
cr
dlp
pg
stc
cbc
cc
cg
plg
plg
soe
pbr
ilc
lmm
aa
cet
cbm
f
vl
br.l.
br.2
h
oe
sg
tm
nr
lcm
c
sh
glr
gim
gip

base.

In Fig. 30 the oesophagus is shown with crop and gizzard cut open laterodorsally on the left side. The long salivary glands (sg) can be seen with their posterior tips superficially attached to the extreme anterior end of the crop (c). The interior of the walls of the crop is specialized and its histology was given by Lemche (1956). Dorsally it is smooth and thin-walled, whilst the inner surface of the ventral walls is thrown into transverse folds ending on the left side in a ridge of pigmented glandular cells. This ridge ends between two of the gizzard plates (gip) at the entrance to the gizzard. The gizzard muscle (gim) is well marked and forms a continuous encircling sheet of fibres, unlike the condition in *Philine* (Fig. 11) where the muscles lie in blocks between the plates, as described by Förster (1934).

Lemche (1948) described the genus *Retusa* as being without a radula. In all species examined this has been so, there being a complete absence of jaws, radula and associated musculature. The walls of the buccal region are unthickened and not strongly muscular, unlike the other genera studied. There is no obvious division between oral tube and buccal cavity. The walls are longitudinally folded, and the nerve ring, with its large ganglia (Fig. 31) surrounds the oral region. The oesophagus leaves posterodorsally and on its junction with the posterior buccal wall lie the buccal ganglia linked by a short commissure, as in *Cylichna*. The cerebro-buccal connective leaves the cerebral ganglion on its inner anteroventral surface, as in *Cylichna* and *Philine*. A nerve runs from this connective to the lateral walls of the buccal region as in these animals. The extrinsic muscles of the region are usually twisted in such a way that the pairs appear asymmetrical. Many small circumoral muscles are present amongst which 2 small pairs of muscles (1 dorsal, 1 ventral) pass forward to their origins. The insertions of these 2 pairs lie just posterior to the nerve ring, through which they pass. These corres-spond in position to pairs I and VI of *Philine* and to the dorsal and ventral protractors (Fig. 28, adp, avp) running forward from the region of the anterior constriction in *Cylichna*. A large group of muscle fibres (Fig. 31, lbd) leaves the anterolateral walls to reach insertions amongst the fibres of the lateral part of the columellar muscle. These lateral groups could, on contraction, considerably dilate the anterior part of the buccal region in feeding (p 326). In a position to retract the buccal region are a pair of long flat muscles (brm) inserting posterolaterally so that fibres enter both above and below the cerebrobuccal connective, most being below it. These originate from the columellar muscle and may be traced back to its more posterior lateral fibres. A pair of minute salivary glands is present, discharging just anterior to the buccal ganglia.

The long oesophagus dilates into a large crop (Figs. 24, 31, c) the entrance to which is surrounded by a sphincter muscle. The crop is thin-walled and becomes considerably folded when empty. It may also push back between the gizzard plates (gip). These are 3 in number as in *Philine*, *Scaphander* and *Cylichna*. The gizzard is more open anteriorly and the plates are not smooth as in the other genera. Posteriorly each plate has a solid pyramidal projection into the lumen with several rounded tubercles anteriorly. The position of the gizzard in the body varies according to the degree of contraction of the specimen. Externally *Retusa* (Fig. 24), like *Acteon* and *Cylichna*, is divided into an obvious head (cr), neck region (nr) and visceral part (vr). The neck and part of the head are often drawn back under the mantle skirt (Fig. 24) or even further, when the whole animal disappears into its shell. The foot is relatively small. The gizzard may be seen by transparency, and in a relaxed animal lies just posterior to the neck region. It may, however, be brought forward to the anterior part of the neck, especially if the animal is slightly contracted, in which case the crop lies within the head. *R. obtusa* has been seen extruding a rissoid through the mouth

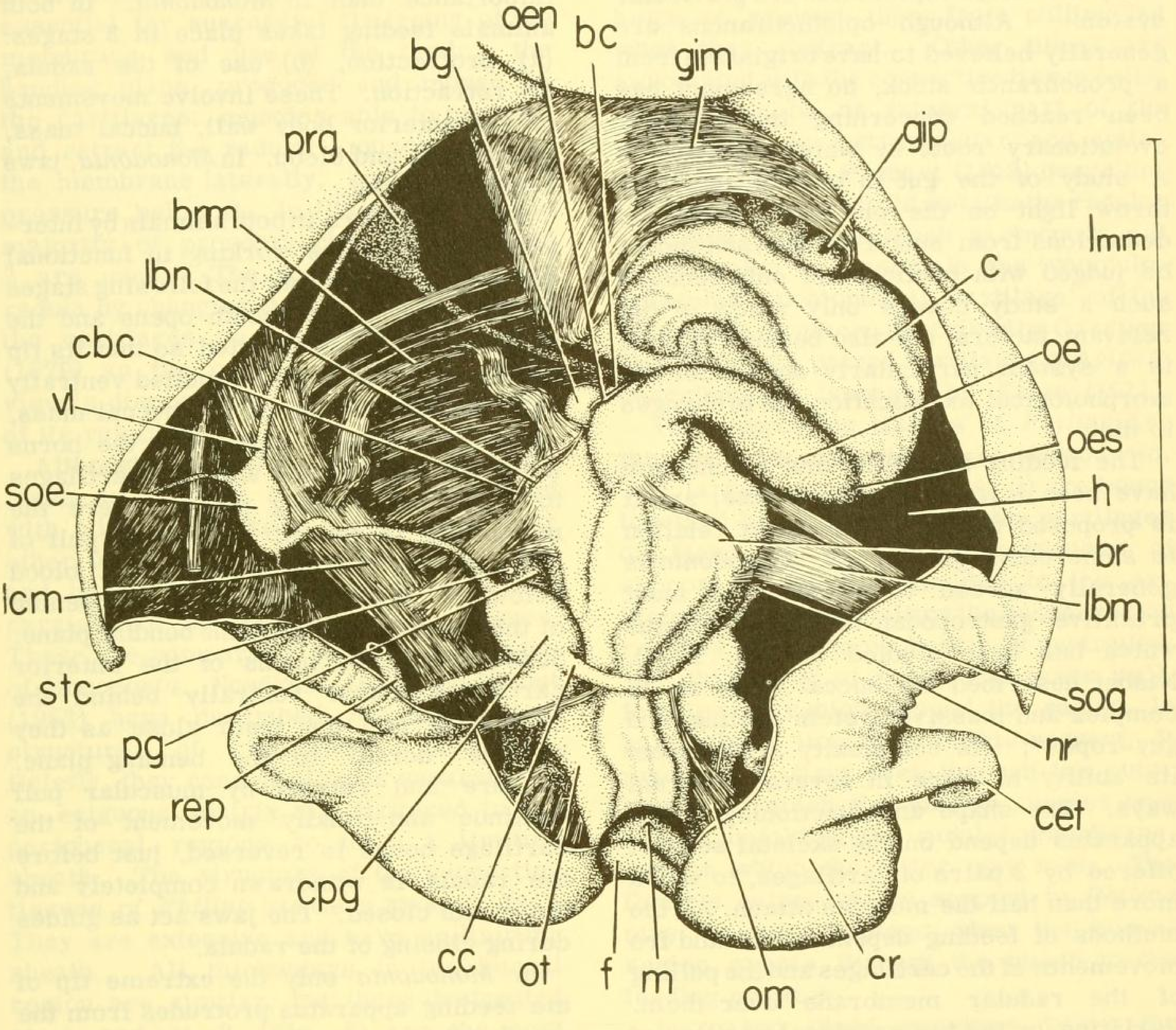

FIG. 31. *Retusa*. Anterior region opened by a mid-dorsal longitudinal cut. The major part of the reproductive system has been removed. bc, buccal commissure; bg, buccal ganglion; br, buccal region; brm, buccal retractor muscle; c, crop; cbc, cerebrobuccal connective; cc, cerebral commissure; cet, cephalic tentacle; cpg, cerebropleural ganglion; cr, cephalic region; f, foot; gim, gizzard muscle; gip, gizzard plate; h, haemocoel; lbm, lateral buccal muscle, lbn, lateral buccal nerve; lcm, lateral part of columellar muscle; m, mouth; nr, neck region; oe, oesophagus; oen, oesophageal nerve; oes, oesophageal sphincter; om, oral muscle; ot, oral tube; prg, parietal ganglion; pg, pedal ganglion; rep, reproductive system; soe, supra-oesophageal ganglion; sog, sub-oesophageal ganglion; stc, statocyst; vl, visceral loop.

after bringing the crop well forward. It is possible that the crop may roll inside out to extrude material. Lemche (1956) described *Retusa* as expelling food from its crop when it withdraws into its shell, but this does not always occur even when the crop is fairly full.

DISCUSSION

An unspecialized body plan is regarded as primitive, and its evolutionary possibilities are wide. More advanced animals may elaborate and emphasize one or another of these, and it is of interest to study the varied exploitation of a particular system. Although opisthobranchs are generally believed to have originated from a prosobranch stock, no agreement has been reached concerning the probable evolutionary route by which they arose. A study of the gut in both groups may throw light on the problem. However, deductions from such a comparison should be judged with caution, not only because such a study covers only a few of the relevant factors, but also because the gut is a system particularly susceptible to morphological modification due to changes in diet.

The feeding apparatus and mechanism have been investigated in *Philine*, and it is proposed to discuss these in relation to some other gastropods. *Monodonta* is generally agreed to possess the most primitive gastropodan feeding apparatus which has been studied (Nisbet, 1953). Nisbet described the buccal mass as "a complex and massive system of slings and guy-ropes"; its complexity arises from its ability to work in several different ways. The shape and functioning of the apparatus depend on the skeletal support offered by 2 pairs of cartilages, to which more than half the muscles attach. All the methods of feeding depend on to and fro movements of the cartilages and the pulling of the radular membrane over them. Variation in the topographical position of the buccal mass is decided by the balance of opposing actions in certain muscles, whilst others maintain the relative positions of component parts.

In *Philine*, the buccal apparatus is less complex, because specialized for a narrower range of feeding methods. The movements required are brought about by a less elaborate interplay of muscles and the shape is maintained by supporting tissues, which also provide a base for muscle attachment. The functioning of the radula does not depend on to and fro movements of the radular membrane relative to the supporting tissue. The degree of protraction and retraction of the buccal mass is much greater, and in the process blood pressure is of more importance than in *Monodonta*. In both animals feeding takes place in 3 stages: (a) protraction, (b) use of the radula, (c) retraction. These involve movements of the anterior body wall, buccal mass, oesophagus and blood. In *Monodonta*, jaws also play a part.

Feeding occurs in both animals by interaction of muscles working in functional groups. In *Monodonta* the following stages are evident. The mouth opens and the buccal mass is protracted so that its tip protrudes. The radula is pulled ventrally past the angular tip of the buccal mass, which is pressed forward by the horns (anterior tips) of the anterior cartilages to form the bending plane. Here the membrane is tensed by lateral pull of muscles and by the pressure of blood below it. Tension promotes the opening of the teeth as they pass the bending plane. Subsequently the horns of the anterior cartilages rotate ventrally behind the membrane and the teeth close as they become dorsal to the bending plane. Closure and retreat by muscular pull continue and finally movement of the cartilage horns is reversed, just before the radula is withdrawn completely and the mouth closed. The jaws act as guides during closing of the radula.

In *Monodonta* only the extreme tip of the feeding apparatus protrudes from the mouth; thus many of the muscles causing the necessary movements are able to insert on the body wall. In *Philine*, where the buccal mass operates outside both buccal and body cavities, the possible areas for muscle attachment are less extensive. Only those muscles determining the position of the buccal mass relative to the body cavity attach it to the body wall. All musculature involved in moving the radula and maintaining the relative positions of components of the buccal mass is enclosed within the latter.

The radular sac and radular membrane of *Monodonta* are much longer than those of *Philine* and many muscles are attached to both. These arrangements are necessary for the mode of action of the radula.

In *Monodonta* the following 4 factors are essential for successful flattening of the membrane and use of the teeth: the bending plane, produced and moved by the cartilages; muscles able to protract and retract the radula; muscles pulling the membrane laterally; control of blood pressure below it. In *Philine*, unlike the majority of prosobranchs, only the last 2 are used. The method of using the radula by changing its position relative to the cartilages was regarded by Geddes (1879) as the only possible one. This view is disproved by *Philine* and a number of its relatives.

Although, in *Philine*, the use of cartilages as pivoting structures associated with a bending plane is superfluous, their other functions - as preservers of shape and bases for muscle attachment- are carried out by the supporting tissues. These are comparable with the cartilages of *Monodonta*. Nowikoff (1912) and Nisbet (1953) have described the histological structure of molluscan cartilages. Briefly, they consist of cells separated by an exiguous matrix and flattened in the peripheral regions to form a limiting sheath. The structure of the supporting tissues of *Philine* has been given (p 294). They are extensive and have no limiting sheath. All thickenings in the buccal region are similar, but those designated st 1 and st 2 (Fig. 8) are the most marked. The means by which the structure achieves its firmness has not been fully investigated. It appears to be partly due to cell inclusions (Gabe & Prenant, 1952) and to a turgidity which may arise from osmotic uptake. The possibility of inflow of blood is unlikely for several reasons: the tissue has not been found in a collapsed condition and does not alter in size or consistency when cut open; intercellular spaces are not extensive, nor has colour entered the supporting tissues on injecting the blood system, although it has sometimes penetrated the thickened buccal mass wall. The connective tissue cells are large and vacuolated, whilst firmness is also promoted by the fibres present. Inserting muscle fibres form a meshwork between the cells and their interweaving helps to prevent them from pulling out when they contract. Other fibres are associated with the connective tissue cells. These may be an integral part of the cell walls, or extracellular and collagenous. Gabe & Prenant (1952) described the tissue as chondroid and like the radular cartilage of prosobranch gastropods. It seems also to resemble the 'vesiculo-muscular odontophoral cartilage' of the pulmonate *Lymnaea* described by Carriker (1946) and the paired cartilages of *Aplysia* described as 'spongy' by Eales (1921).

The supporting tissues of *Philine* are thus not so discrete as in *Monodonta*. The largest areas (st 1, st 2) are bound together by muscles as are the cartilages of *Monodonta*. The extensiveness of support in *Philine* is due to the extremely exposed position the buccal region reaches when the proboscis is protruded. The thickening of the buccal mass wall, forming a cushion around the radula, is particularly important in this respect. It provides a firm area through the outer layers of which the oblique muscles may act in unfolding the radular membrane, and on which the latter may rest. The flexible nature of the support in *Philine* may be an advantage when the buccal region passes through the mouth to the feeding position.

Increased blood pressure below the radular membrane is important in both *Monodonta* and *Philine* (p 319-320), but in the latter a further function of such pressure changes is to help in protrusion of the proboscis. Inflow of blood to this has been described (p 323-325) and is due to redistribution of the available fluid. This is brought about by muscular constriction of the anterior sinuses and use of the buccal region of the gut as a plunger whilst it is being protracted.

The histological structure of the oesophagus is such that it may change shape considerably and be readily swollen to form the dorsal part of the proboscis. Changes in distribution of blood within this part are due to muscular movement of its walls (p 321). A further adaptation of the blood system is associated with completing withdrawal of the proboscis and involves the haemal sacs (p 315, 325).

The grabbing motion of the radula of *Philine* is superficially like the plucking action which may occur in *Monodonta* (Nisbet, 1953) when the snout is not firmly pressed to the substratum. This action involves a quick closing of the teeth when the radula is pulled back over the bending plane, which itself moves ventrally. Closing in *Philine* is not brought about in this way. Plucking, as in *Monodonta*, has been adopted by many gastropods, for instance *Physa* (Eigenbrodt, 1941; Nisbet, 1953), and has superseded other ways of using the radula. It is an emphasis of the rotatory phase of feeding. Some prosobranchs have adopted the forward pushing of the radula over the substratum: *Patella* (Ankel, 1938; Eigenbrodt, 1941; Nisbet, 1953), *Haliotis* (Crofts, 1929), whilst others use only the brushing motion also seen in *Monodonta*, e.g. *Littorina* (Ankel, 1937; Nisbet, 1953). With reference to *Philine*, the most interesting prosobranch group to have adopted a plucking or carding use of the radula is that of the carnivorous stenoglossans. These show further superficial resemblances in that they feed with a proboscis and have a relatively shorter buccal mass than *Monodonta*. The radula is like that of *Philine*, having a formula 0.1.1.1.0, with lateral teeth which are large and hook-shaped.

The most complete account of the stenoglossan feeding apparatus has been given by Carriker (1943) for *Urosalpinx*. The radular teeth are erected by passing out over the bending plane as in *Monodonta*, but on closing, during the reverse movement, the arc through which the teeth move is greatly accentuated by longitudinal folding of the radular membrane into a deep groove. This results in a strong gripping action. The last part of the process appears very similar to the method used by *Philine*, which seems to have emphasized it as the sole means of achieving an inward swing of the teeth to grasp prey. The radular membrane, after being flattened by lateral muscluar pull, together with increased subradular blood pressure, is infolded deeply into a longitudinal groove to close it, just as in the stenoglossans.

The proboscis of *Urosalpinx* and other stenoglossans is a structure derived from an extension of the anterior region of the body wall and is not a gut extrovert as is that of *Philine*. Carriker (1943) described its protrusion by means of 'hydrostatic pressure and circular muscles in its walls' and stated that it is 'retracted by longitudinal proboscis retractors'. Thus in stenoglossans also, blood pressure is of greater initial importance in obtaining food than in (for instance) *Monodonta*, since the feeding position cannot be achieved without it. Long retractor muscles are present in both *Urosalpinx* and *Philine* and are necessary for withdrawal of the large protruded structure.

The proboscides of stenoglossans and *Philine* are analogous in that each is a means of placing the buccal mass in such a position that it may be more easily manoeuvred around the food. The distance through which the buccal mass of the stenoglossan may be advanced is much greater than in *Philine*, although it remains passive in the process and does not move forward relative to the buccal cavity, owing to its situation at the tip of the elongated inturned anterior end of the body. When the latter is extended it forms a very mobile structure, slender and well suited for a specialized carnivorous feeding method. Thus, Ankel (1938) quoted the insertion of the proboscis of *Sycotypus* into the shell of its prey, and *Urosalpinx* (Carriker, 1943) feeds in a similar way on oysters. By use of the proboscis in this way, stenoglossans are able to reach otherwise inaccessible parts of their prey. In *Philine*, unlike the stenoglossans, the method of bringing the buccal mass-forward represents an emphasis of the protraction which occurs in all gastropods. *Philine* may either protract the buccal mass alone (p 315) or, by augmenting changes in blood pressure, protrude it as part of the proboscis. This faculty allows wider possibilities in ways of feeding. The method used is suited to the nature and distribution of the food. Firstly, when readily accessible prey is available, the buccal mass is protruded, grabbing it with great accuracy as described on p 284. Secondly, when prey is less accessible, perhaps buried in sand, the proboscis is used. The buccal mass then projects downwards (Fig. 10), so that it is able to grope in the sand, and with the aid of the bending and rotatory movements described (p 321) to disinter the food. With the dorsal part of the proboscis used as a basis for muscular and blood movements the ventral part may be placed with great nicety and remain exposed for long periods. This arrangement enables *Philine* to wait for the emergence of such an animal as *Pectinaria* from shelter after sensing the inhalant respiratory or exhalant rejection currents of the worm (Watson, 1928). Thirdly, the exposed condition of the oesophagus, when the proboscis is protruded, may enable *Philine* to use suction, which probably plays a part in food intake in most gastropods. It is usually oesophageal and peristaltic in origin, and implies the presence of dilator muscles. In general, the buccal cavity or oral opening is quickly enlarged when required. In the proboscis of *Philine*, the oesophageal entrance has replaced the oral opening and must itself widen. Changes in the degree of relaxation of its intrinsic musculature may allow widening and peristalsis of the part of the oesophagus within the proboscis has been observed. This activity may draw food particles entering by ciliary action (p 321) into the more posterior regions of the gut and suck in large quantities of small food, such as Foraminifera. The 2 actions of the proboscis - to disentangle food and to suck it in - may be used together. Thus the proboscis need not necessarily be completely withdrawn in order to take in food. Its entrance can function as a secondary mouth whilst the true mouth is lost as the site of direct communication between buccal cavity and outside world. This mode of feeding occurs in situations where food is relatively small and plentiful and allows slow and accurate intake. Where larger prey has been manipulated by the radular teeth and buccal mass on the ventral part of the proboscis, it may be necessary for the food to be dragged in as an accompaniment of complete retraction of the anterior part of the gut. In this case, and in feeding by simple protraction of the buccal mass alone, the true mouth acts in the normal way as the place where food first enters the gut.

The evolutionary trends which have been observed in the gastropods considered have been these: firstly, the feeding method of a primitive prosobranch (the trochacean, *Monodonta*) is versatile and includes various movements. The second stage of evolution has concerned amplification of a particular movement resulting in more specialized feeding with more restricted usage of the buccal apparatus and consequent simplification; at this stage are the docoglossans which have emphasized forward rasping, the taenioglossans, brush-feeders, and a pulmonate, *Physa*, which uses plucking action. The stenoglossans are at a third stage, since not only have they elaborated and emphasized a particular basic action - plucking - but have added further modifications of their own which lead to greater efficiency. *Philine* represents a fourth stage, probably reached by an entirely different evolutionary route, in which the original action, dependent on a bending plane, has been completely replaced. Thus, it grasps by folding the radular membrane longitudinally, using this procedure alone as the means of closing the teeth. Part of the basic bending plane or strap and pulley process, however, (lateral pull and subradular blood pressure) is still used in conjunction with this to allow reopening of the teeth. *Philine* also augments another process, that of suction, which is present as an integral though often minor part of feeding in other gastropods. Although the tendency to specialize in particular methods and lose others is readily seen as it occurs in living gastropods, these animals may all represent separate lines of evolution. Similarities have arisen by convergence due to common problems such as similar food, or the necessity for accurate placing of the feeding apparatus.

Information on such trends in opisthobranchs is much more scanty than in prosobranchs. As regards those briefly discussed in section II, in common with *Philine* they do not possess the strap and pulley arrangement of cartilages and radula, but have vesiculo-muscular supporting tissue for muscle attachment. All feed on slow moving food often with a hard protective covering.

It is likely that *Scaphander* feeds in a similar manner to *Philine* since its feeding apparatus is almost exactly the same and it lives in a similar habitat, taking the same food: indeed, it may be considered an outsize *Philine*. Both have the following anatomical adaptations:

1. *Buccal mass*

(a) The muscles concerned in its movements, as distinct from those causing changes in topographical position, lie within it, and so are efficient whatever its position.

(b) The radular sac is short. This is a general feature amongst carnivorous gastropods that may occur either because the wearing out of teeth is not particularly swift, or may reflect greater efficiency in speed of tooth production.

(c) The radular membrane is short, with the minimal number of functional teeth compatible with efficient gasping of prey. Correlated with reduction in length is the elaboration of a new method of opening the teeth.

(d) The supporting tissues of the buccal mass are not rigid. This is advantageous for movement of the buccal mass through the mouth and is compatible with the new method of tooth function.

(e) Jaws have been lost for similar reasons.

2. *Buccal region*

(a) The mouth and oral tube are very distensible and allow the buccal mass and large hard prey to pass through them.

(b) The oesophagus is capable of great extension and expansion, correlated with its functions as a sucking organ and support for the ventral part of proboscis.

(c) The retractor muscles are capable of great change in length.

(d). Small muscles attaching the buccal region to the body wall have been lost.

(e) The salivary glands are small and unattached except by their ducts.

3. *Nervous system*

(a) The ganglia are placed in a compact group at each side of the nerve ring. Few nerves leave their medial surfaces, and these only at the anterior edge (cbc, c6, cc2, pc3), thus minimizing possible damage as the buccal region and its musculature pass through.

(b) The cerebral and pedal commissures are long, the nerve ring wide, allowing a maximum of space for the passage of the buccal region

(c) The long cerebrobuccal connectives are accompanied by muscle fibres which ensure that the buccal ganglia maintain their position relative to the buccal part of the gut. Lemche (1956) suggested, in discussing *Cylichna*, that such fibres 'prevent entangling of the buccal connective when the pharynx is protracted'.

(d) Nerves which supply regions of the gut liable to stretching in the formation of the proboscis, follow a meandering course (e.g. b4, bt, c6 oen) and are often enclosed in muscular sheaths (oen). Such sheaths were first described in *Archachatina* by Nisbet (1961).

4. *Blood system*

(a) The anterior part of the haemocoel is large so that the anterior region of the gut is not restricted by other systems and fluid is available for eversion of the proboscis.

(b) The anterior aorta allows a large flow of blood; it can be constricted in two places allowing fluid to be restricted to a particular area.

(c) In *Philine* there are haemal sacs which are used as a reservoir for fluid returning down the anterior aorta.

(d) In *Philine* anterior sinuses act as reservoirs from which blood may be forced forward and made available for pushing out the proboscis.

(e) In *Scaphander* a horizontal septum below the gut divides the anterior part of the haemocoel into upper and lower parts; this arrangement may be functionally equivalent to the reservoirs of *Philine*.

(f) The buccal artery leads to a sinus below the radular membrane, which can be shut off from the rest of the vascular system.

These characteristics adapt the anterior part of the gut as an extrovert for use in feeding. Some (for instance 1: a; 2: c, d; 3: a, b, d; 4: a, b, f) appear essential, others advantageous. The extrovert allows feeding by both grabbing and sucking or by a combination of the two.

The remaining opisthobranchs considered will be discussed with reference to the method by which they feed. *Acteon* lacks adaptations considered essential for a proboscis. It is, however, able to eat sedentary worms, as *Philine* and *Scaphander* do. Since it has no crushing gizzard it is unable to make use of prey with hard parts, such as bivalves. *Owenia*, on which it feeds at Rhossili, South Wales, has a tube composed of sand grains, which is flexible, unlike that of *Pectinaria* (an important prey of *Philine* and *Scaphander*). *Acteon* is probably able to suck the worm out of its tube and take it in as follows: dilatation of the oral tube by the extrinsic muscles (ex A, ex D, Fig. 25) and expansion of the oesophagus by contraction of the oesophageal muscles (oem) provide an area of low pressure sufficient to draw prey in. Contraction of extrinsic muscles B and C tends to protract the buccal mass and to draw the lateral cushions of the buccal mass apart. This separates the 2 halves of the radular membrane so that the worm, sucked in and held by the jaws, is placed between them, prevented from escaping by the back-pointing radular teeth. Subsequent passage of the worm into the oesophagus is aided by peristaltic movements of the oesophageal walls which are prevented from moving forward by dilator muscles (oem) attaching them to the body wall. Saliva probably coats hard particles entering the gut, so that its walls are not damaged. This method of feeding may well be possible without any alteration in the angle of the teeth. The use of recurved teeth is not uncommon in gastropods and occurs in such widely separated animals as the ptenoglossans (Fretter & Graham, 1962), the slug *Testacella* (Ankel, 1938; Quick, 1960), and the Naticidae (Ankel, 1938) in which a dorsal palatine tooth prevents escape of prey. No observations have been made on *Acteon* in the process of feeding, but it is unlikely to protract the buccal mass far, since it has no retractor muscles and suction is probably of great importance. Erection of teeth is dispensed with but they may be used to drag in prey as in ptenoglossans and *Testacella*.

Although *Cylichna* possesses adaptations which might be compatible with eversion of the anterior end of the gut, accompanying features which would not easily permit such eversion include the great elongation of the oral region, the comparative weakness of the retractor muscles (br 1, 2) and the possession of jaws. It is probably able to feed successfully without the aid of a proboscis. The function of the greatly emphasized anterior glandular region is not known. Sterner (1912) described the glands of the anterior regions of some tectibranchs, including

Philine and *Acteon:* these are not of great extent. *Cylichna* appears to have specialized in glandular development since it also possesses a glandular ridge (Fig. 30, glr) within the crop, which has been described by Lemche (1956) and which does not appear to be homologous to any prosobranch structure described by Graham (1932) or Fretter & Graham (1962).

The muscular posterior part of the buccal region of *Cylichna*, containing the buccal mass and jaws, is probably pulled forward through the nerve ring and up to the mouth in order to feed, and this is likely to occur as Lemche (1956) suggested.

Opening and closing of the teeth probably occur by a means similar to that of *Philine* since the intrinsic musculature of the buccal mass is essentially similar, as has been described (p 333-334). Thus *Cylichna* uses the grabbing motion of *Philine* without protrusion of the buccal mass or particular emphasis on sucking. It has retained jaws.

Since *Retusa* is devoid of buccal mass and jaws it can employ only suction as a means of obtaining food. It is brought about by great dilatation of the buccal cavity, using the lateral buccal dilators (Fig. 31, lbm), whilst the entrance to the crop is constricted to prevent regurgitation and the posterior end of the buccal cavity held back by a pair of retractors (brm). *Retusa* has emphasized suction to such a degree that it has lost the buccal equipment of other gastropods, which would present an impediment to the passage of food. The large size of the crop and gizzard (Figs. 24, 31,c, gi) allows ingestion of much material.

There are few accounts of the buccal apparatus of opisthobranchs and they include little information on feeding methods. In none has the degree of protrusion of the buccal region described been so great as in *Philine*. The herbivorous tectibranchs *Haminea* and *Bulla* may protrude the buccal mass to a certain extent (Guiart, 1901), but the oesophagus does not also emerge to form a large extrovert. Berrill (1931) described a temporary feeding mechanism in the veliger of *Bulla hydatis*, in which the buccal mass is extruded so that setae on its tip project divergently: on retraction they close together and are withdrawn. *Gastropteron*, in which the buccal anatomy, nervous and vascular systems are like those of *Philine* (Vayssière, 1880), is also able to protract the buccal mass to some extent. This carnivore may feed as *Cylichna* does, or be capable of protruding the gut to a greater degree, despite the presence of jaws, since it has more adequate retractor muscles. In all these animals protraction of the buccal mass is probably more marked than in many prosobranchs, but there is no proboscis comparable to that of *Philine*. Thompson & Slinn (1959) however have described *Pleurobranchus*, which has a gut extrovert used in feeding. This eversion seems to involve extrusion of the elongated oral tube only, and is thus again unlike that of *Philine*.

Eales (1921) and Howells (1942) both described the process of feeding in aplysians: no extrovert is formed and jaws are used in conjunction with the radula. *Aplysia* holds seaweed within the lips and jaws, closes the radular teeth around them and then tightens the grip by contraction of a sphincter round oral tube and mouth (I3 of Howells, corresponding apparently to vcm of *Philine*), simultaneously pulling the buccal mass back so that a piece of weed is torn off. The radular teeth then release the weed to the oesophagus. The movements of the buccal mass within the buccal cavity are similar to the rising and sinking movements described in *Philine* (p 315, 319). This is to be expected since the musculature used appears similar to that of *Philine*. The following muscles apparently correspond (Howell's names are given first): E1 = proboscis retractor II of *Philine;* E2 = retractor III; I1 - longitudinal intrinsic musculature of the oral tube of *Philine;* I2 = superficial buccal musculature; I3 = ventral circular muscle; I4 = radular occlusor; I5 = buccal tensor 3; 16 = anterior transverse muscle. Since *Aplysia*, like *Acteon*, has no retractor muscles, it is unlikely to protrude the buccal mass in the manner suggested by Guiart (1901). The tectibranch *Akera bullata* described by Morton and Holmes (1955), also feeds without a proboscis and its buccal mass and activities are exactly like those of *Aplysia*.

Boettger (1954) gave a detailed classification of opisthobranchs, but the results of the present work do not allow much comment on this: the gut of these animals has undergone such a high degree of adaptation for efficient feeding, that it cannot be used as a reliable guide to evolutionary trends. The Philinidae and Scaphandridae are certainly close, as Boettger suggested; *Retusa*, on the characteristics of its buccal region, cannot be placed with any accuracy, due to the loss of buccal apparatus, but is likely to be advanced. *Acteon* is not very like the other genera studied, and its buccal region does not seem unspecialized. Although *Acteon* shows a mixture of prosobranch and opisthobranch characters and is therefore probably primitive in some respects, its buccal region is unlike that of any ancestral form likely to have given rise to *Philine*, *Scaphander* or *Cylichna*.

ACKNOWLEDGEMENTS

The major part of this work was carried out at the University of Reading and my thanks are due to Dr. V. Fretter and Professor A. Graham for guidance and help. Dr. R. H. Nisbet, of the Royal Veterinary college, London, provided valuable constructive criticism and advice on the use of the stimulator. Three months were spent at the marine laboratories at Plymouth, Helsingør, Denmark, and Menai Bridge, Anglesey, to the directors of which I am grateful for facilities. I should like to thank those who provided specimens and advice, the Department of Scientific and Industrial Research and the University of Reading for financial aid.

BIBLIOGRAPHY

ALEXANDROWICZ, J. S., 1932, The innervation of the heart of the Crustacea. I. Decapoda. Quart. J. micr. Sci. 75: 181-249.

________, 1960, Innervation of the hearts of *Sepia officinalis*. Acta Zool. Stockh. 41: 65-100.

ANKEL, W. E., 1937, Wie frisst *Littorina*? 1. Radula-Bewegung und Fresspuren. Senckenbergiana 19: 317-333.

________, 1938, Erwerb und Aufnahme der Nahrung bei den Gastropoden. Verh. dtsch. zool. Ges., Zool. Anz. Suppl. 11: 223-295.

BACESCU, M. & F. E. CARAION, 1956, Animale mîncatoare de Foraminifere. Comunicările Acad. Rep. P. Rumania, VI(4): 551-553.

BERRILL, N. J., 1931, The natural history of *Bulla hydatis* Linn. J. mar. biol. Ass. U. K. 17 (2): 567-571.

BOETTGER, C. R., 1954, Die Systematik der euthyneuren Schnecken. Verh. dtsch. zool. Ges., Zool. Anz. Suppl. 18: 253-280.

BROWN, H. H., 1934, A study of a tectibranch gasteropod mollusc, *Philine aperta* (L.). Trans. roy. Soc. Edinb. 58: 179-210.

CARRIKER, M. R., 1943, On the structure and function of the proboscis in the common oyster drill, *Urosalpinx cinerea* Say. J. Morph. 73: 441-506.

________, 1946, Observations on the functioning of the alimentary system of the snail *Lymnaea stagnalis appressa* Say. Biol. Bull., Woods Hole 91: 88-111.

CROFTS, D. R., 1929, *Haliotis*. Liverpool mar. Biol. Coll. Memoir 29, Liverpool, University Press.

CUVIER, G. L., 1802, Mémoire sur la *Bullaea aperta*. Ann. Mus. Hist. Nat. 1: 156-164.

________, 1815, Mémoire sur les Acères, ou Gastéropodes sans tentacules apparents. Ann. Mus. Hist. Nat. 16: 1-18.

EALES, N. B., 1921, *Aplysia*. L. M.

B. C. Memoir 24, Liverpool, University Press.

EIGENBRODT, H., 1941, Untersuchungen über die Funktion der Radula einiger Schnecken. Z. Morph. Okol. Tiere 37: 735-791.

FORSTER, H., 1933, Beiträge zur Histologie und Anatomie von *Philine aperta* L. Diss. Kiel. (Risse-Verlag, Dresden-A, 1.).

FRETTER, V., 1939, The structure and function of the alimentary canal of some tectibranch molluscs, with a note on excretion. Trans. roy. Soc. Edinb. 59: 599-646.

FRETTER, V. & A. GRAHAM, 1954, Observations on the opisthobranch mollusc *Acteon tornatilis* (L.). J. mar. biol. Ass. U. K. 33: 565-585.

________, 1962, British Prosobranch Molluscs, their functional anatomy and ecology. Ray Soc., Lond., 144.

GABE, M. & M. PRENANT, 1952, II. Recherches sur la gaine radulaire des mollusques. 5. L'appareil radulaire de quelques opisthobranches céphalaspides. Bull. Lab. marit. Dinard 37: 13-17.

________, 1953, Données morphologiques sur la région antérieure du tube digestif d'*Acteon tornatilis* L. Extrait Bull. Soc. zool. Fr. 78: 36-44.

GEDDES, P., 1879, On the mechanism of the odontophore in certain Mollusca. Trans. zool. Soc. Lond. 10: 485-491.

GRAHAM, A., 1932, On the structure and function of the alimentary canal of the limpet. Trans. roy. Soc. Edinb. 57: 287-308.

GUIART, J., 1900, Les Mollusques Tectibranches. Caus. sci. zool. Soc. Fr. 1: 77-132.

________, 1901, Contribution à l'étude des gastéropodes opisthobranches et en particulier des céphalaspides. Mém. Soc. zool. Fr. 14: 1-219.

HOWELLS, H. H., 1942, The structure and function of the alimentary canal of *Aplysia punctata*. Quart. J. micr. Sci., 83: 357-397.

JEFFREYS, J. G., 1865, British Conchology, 3. Lond. van Voorst.

LACAZE-DUTHIERS, H. de, 1872, Otocystes ou capsules auditives des mollusques (gastéropodes). Arch. Zool. exp. gén. 1: 97-166.

________, 1898, Les ganglions dits palléaux et le stomatogastrique de quelques gastéropodes. Arch. Zool. exp. gén. 6: 331-428.

LEMCHE, H., 1948, Northern and Arctic tectibranch gastropods 1-2. Kgl. Danske Selsk. Biol. Skr. 5(3): 1-136.

________, 1956, The anatomy and histology of *Cylichna* (Gastropoda Tectibranchia). Skr. Zool. Mus. Copenhagen 16: 1-278.

MORTON, J. E. & N. A. HOLMES, 1955, The occurrence at Plymouth of the opisthobranch *Akera bullata*, with notes on its habits and relationships. J. mar. biol. Ass. U. K. 34: 101-112.

NISBET, R. H., 1953, The structure and function of the buccal mass in some gastropod molluscs. 1. *Monodonta lineata* (da Costa). Ph.D. Thesis, University of London.

________, 1961, Some aspects of the structure and function of the nervous system of *Archachatina* (*Calachatina*) *marginata* (Swainson). Proc. roy. Soc. B, 154: 267-287.

NOWIKOFF, R. H., 1912, Studien über das Knorpelgewebe von Wirbellosen. Z. wiss. Zool. 103: 661-717.

PELSENEER, P., 1893, Recherches sur divers opisthobranches. Mém. Sav. étr. Acad. R. Belg. 53: 1-157.

PRUVOT-FOL, A., 1954, Mollusques opisthobranches. Faune de France 58.

QUICK, H. E., 1960, British slugs (Pulmonata; Testacellidae, Arionidae, Limacidae). Bull. Brit. Mus. Zool., 6 (3): 105-226.

RUSSELL, L., 1929, The comparative morphology of the elysioid and aeolidioid types of the molluscan nervous system, and its bearing on the relationships of the ascoglossan nudibranchs. Proc. zool. Soc. Lond. 14: 197-233.

SMITH, J. E., 1946, The mechanics and innervation of the starfish tube foot - ampulla system. Phil. Trans. B. 232: 279-310.

STERNER, R., 1912, Die Hautdrüsen bei

den Cephalaspidea. Bull. Intern. Acad. Sci. Cracovie. Cl. Sci. Math. nat. B.: 1001-1042.

TCHANG-SI, 1934, Contribution à l'étude des opisthobranches de la côte de Tsingtao. Contr. Inst. Zool. Peiping 2(2): 1-148.

THOMPSON, T. E. & D. J. SLINN, 1959, On the biology of the opisthobranch *Pleurobranchus membranaceous*. J. mar. biol. Ass. U. K. 38: 507-524.

VAYSSIERE, M. A., 1880, Recherches anatomiques sur les mollusques de la famille des Bullidés. Ann. Sci. nat. Zool. (6), 9: 1-123.

WATSON, A. T., 1928, Observations on the habits and life-history of *Pectinaria* (*Lagis*) *koreni* Mgr. Trans. Liverpool biol. Soc. 42: 25-60.

RESUMEN

ESTUDIOS SOBRE LA ESTRUCTURA Y FUNCION DEL APARATO ALIMENTADOR DE *PHILINE APERTA*, Y COMPARACION CON OTROS OPISTOBRANQUIOS

Se estudia la anatomía bucal, y el suministro vascular y nervioso en la parte anterior del cuerpo de *Philine aperta* (L.). El funcionamiento es explicado en base a observaciones sobre la alimentación, la relación variable de las partes constituyentes del aparato bucal, y el resultado de estimulación experimental e inyecciones.

La paredes de la región bucal estan provistas de músculos intrínsicos, capaces de grandes cambios en forma: encierra una masa bucal compacta en la cual la rádula se soporta por grandes músculos y un tejido maleable de células vacuoladas, con inclusiones celulares y fibras musculares repartidas. Este tejido de soporte sirve también de base para la adherencia muscular, mientras un par de grandes músculos actua en el cierre de la rádula, la cual al abrirse lo hace por medio de dos juegos de fibras musculares que corren en la pared de la masa bucal. Cuatro pequeños pares de tensores bucales mantienen junta la masa bucal. La musculatura intrínsica conserva las formas y relaciones de las partes componentes de la masa bucal, causa sus movimientos de arriba a abajo al pasar los alimentos al esófago e interviene en el movimiento de los dientes.

La región bucal está adherida a la pared del cuerop por seis pares de músculos extrínsicos los cuales determinan su posición topográfica. Al comer, cuatro de estos pares tiran la región bucal hacia adelante y la entera masa bucal es proyectada hacia afuera de modo que la rádula queda en posición anterior a la boca y puede usarse como un garfio. La protrusión puede estar acompañada de extrusión y expansión del esófago anterior para formar una extroversión con inclusión sanguínea, dependiendo de la especialización del sistema sanguíneo y el grado de flojedad de los paquetes del músculo columelar. Estos músculos abren, cierran la boca, y controlan el suministro sanguíneo de las regiones anteriores por su habilidad constrictora sobre la aorta anterior. Esta vaso también puede contraerse posteriormente donde pasa a través del diafragma. Es confluente con muchos sacos hemáticos pequeños y algunos senos anteriores grandes que controlan la protrusión y retracción de la proboscis. El recogimiento depende, en gran parte, de seis pares de retractores proboscidales, los cuales también causan los movimientos rotatorios de la proboscis. La rádula es corta y cada fila de dientes comprende sólo un par único de laterales, que se abren y cierran ampliamente, de modo que otros adyacentes se intercalan, o pueden asir el alimento firmemente. La abertura depende del tiraje de los músculos laterales con presión sanguínea aumentada debajo de la membrana radular, mientras en el cierre se pliega longitudinalmente por tiraje muscular desde abajo.

Mientras que muchos gastrópodos pueden producir protrusión de la masa bucal hasta cierto límite, se demuestra que en *Philine* se extiended más afuera, formando parte de un gran saco extrovertido. Algunos otros opistobranquios se han comparado con *Philine* y se dan sus dietas; de estos, *Scaphander lignarium* (L.) es muy similar aunque el sistema sanguíneo no exhiba tantos cambios adaptivos. *Actaeon tornatilis* (L.), *Cylichna cylindracea* (Pennant) y *Retusa* sp. no usan proboscis; se sugiere el probable metodo alimenticio de estos últimos. *Retusa* has perdido su masa bucal y se alimenta por succión. Tendencias evolucionarias no son facilmente trazables debido a la adaptación extrema de la región bucal y el modo de alimentarse.